Aesculap MINOP® TEAM

Transcranial Endoscope-Assisted Microneurosurgery:
A Practical Atlas

Robert Reisch, M.D., Ph.D.

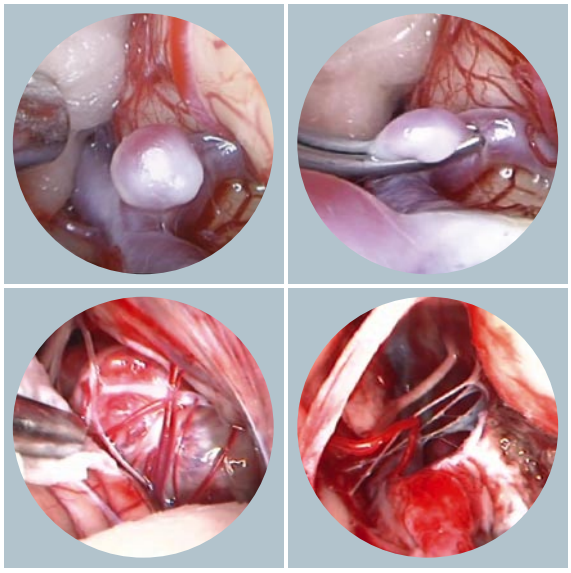

Aesculap Neurosurgery

In collaboration with

Nikolai Hopf, M.D., Ph.D.
Evaldas Cesnulis, M.D.
Axel Stadie, M.D.

Layout and Illustration
Stefan Kindel

Dedicated to Axel Perneczky

B|BRAUN
SHARING EXPERTISE

MINOP TEAM

Surgical Concept,
Technique and Instrumentation in
Minimally Invasive
Transcranial Endoscope-Assisted Microneurosurgery

Robert Reisch

In collaboration with
Nikolai Hopf
Evaldas Cesnulis
Axel Stadie

Layout and Illustration by
Stefan Kindel

Dedicated to Axel Perneczky

Prof. Robert Reisch, M.D., Ph.D.
Centre of Endoscopic and
Minimally Invasive Neurosurgery
Clinic Hirslanden Zurich
Witelliker Strasse 40
8032 Zurich, Switzerland
Email: robert.reisch@hirslanden.ch

Prof. Nikolai Hopf, M.D., Ph.D.
Department of Neurosurgery
Katharinenhospital, Stuttgart
Kriegsbergstrasse 60
70174 Stuttgart, Germany
Email: n.hopf@klinikum-stuttgart.de

Evaldas Cesnulis M.D.
Centre of Endoscopic and
Minimally Invasive Neurosurgery
Clinic Hirslanden Zurich
Witelliker Strasse 40
8032 Zurich, Switzerland
Email: evaldas.cesnulis@hirslanden.ch

Axel Stadie, M.D.
Neurosurgical Department
University Hospital, Mannheim
Theodor-Kutzer-Ufer 1-3
68167 Mannheim, Germany
Email: axel.stadie@umm.de

Stefan Kindel
Graduate in Fine Arts
artepalatina
Hartmannstraße 1
67487 Maikammer
Email: stefan.kindel@artepalatina.de

MINOP® TEAM

Surgical Concept, Technique and Instrumentation in Minimally Invasive **T**ranscranial **E**ndoscope-**A**ssisted **M**icroneurosurgery

In 1924, the famous general and neurological surgeon William Halsted expressed his belief "...that the tendency will always be in the direction of exercising greater care and refinement in operating". Today, on the threshold of the third millennium, this fundamental philosophy of minimally invasive therapy should be emphasised more than ever before, operating with a minimum of iatrogenic trauma whilst achieving maximal surgical efficiency.

In this publication, we provide a contemporary overview on minimally invasive methods in cranial microneurosurgery.

After a brief historical background, the general concept of minimal invasive keyhole techniques is demonstrated placing particular emphasis on preoperative planning and preparation, adequate surgical instrumentation and intraoperative visualisation. Special interest is given to the TEAM-technique, to the complementary use of microscopes and endoscopes in terms of **T**ranscranial **E**ndoscope-**A**ssited **M**icroneurosurgery

Two characteristic minimal invasive approaches are described in detail illustrating the supraorbital and retrosigmoidal keyhole craniotomies. Corresponding illustrative cases are also presented to demonstrate the highly sophisticated TEAM-techniques. Both cases were operated in the Centre for Endoscopic and Minimally Invasive Neurosurgery, Clinic Hirslanden Zurich.

By paying particular attention to surgical practice, the goal of this practical atlas is to offer important tips and ideas providing valuable instructions for everyday use in the field of minimally invasive neurosurgery.

Acknowledgements

Transcranial Endsocope-Assisted Microneurosurgery is a real TEAM-work! We express our gratitude to our colleagues in the Clinic Hirslanden Zurich, Neurosurgical Department Stuttgart University Hospital Mannheim and University Hospital Mainz. Special thanks are given to Zsolt Kulcsár, Daniel Rüfenacht, Isabel Wanke and Stephan Wetzel from the Hirslanden Neuroradiological Department and to neurologist Mima Bjeljac for the fruitful co-operation in the presented illustrative cases. Judith Stadler and Andre Uster performed intraoperative photographs; Adrian C. Sewell supported copy editing

In Memoriam

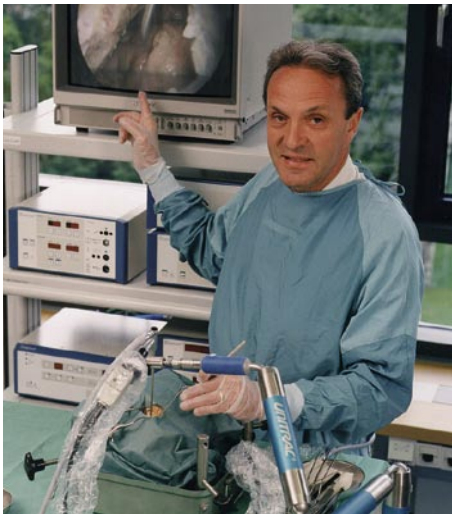

Axel Perneczky * 1.11.1945 † 24.1.2009

Axel Perneczky was born on November 1st, 1945 in the small town of Krasnogorsk in Russian captivity. Only a year later, his family moved to Budapest where he grew up and started medical school in 1964. In 1965, the family took refuge in Vienna, Austria. After graduating in 1971, he entered his training in neurosurgery in 1973 in the Department of Neurosurgery at the University Hospital Vienna under the direction of Professor Koos. Driven by his great interest in microsurgery, he spent a fruitful training with Professor Yasargil in Zurich. Axel Perneczky was announced Professor of Neurosurgery at the University of Vienna in 1980. In 1988, he was given the chair in Neurosurgery at the Johannes Gutenberg-University of Mainz, where he worked until his recent death.

Axel Perneczky dedicated his academic life to the struggle of reducing the surgical risks for his patients. His vision is undoubtedly best described by the term "minimally invasive" concept, a term he coined himself early on in his neurosurgical career. The basic idea of this vision was to enable even complex surgical procedures through less traumatic, stepwise smaller, "keyhole"-like craniotomies. Driven by his clear and strong vision that these aims must also be accomplishable with less invasive surgical strategies, he finally came across endoscopic techniques. From the very first contact with endoscopes, Axel Perneczky believed that this technique was the key to the future of neurosurgery.

Axel Perneczky never tired of teaching his conviction to his pupils and started a series of international meetings on this topic with the 1. International Congress on Minimally Invasive Neurosurgery in 1993 in Wiesbaden, Germany. In the same year he founded the journal "Minimally Invasive Neurosurgery" and acted as its editor in chief until his death.

Axel Perneczky was an extremely charismatic and bright person, patiently listening to his staff neurosurgeons, residents, or any other employee of the department. He was highly regarded and respected by all his patients, colleagues and pupils both in Mainz and throughout the world.

Weighed down by an insidious and progressive illness over the last few years, Axel Perneczky passed away on January 24th, 2009 at the age of 63 years – too early to complete his ambitious work and much too early for his family, friends, and colleagues.

Axel Perneczky is undoubtedly a legend in neurosurgery based on his enormous medical contributions and outstanding personality. His name will always be connected with minimally invasive and endoscopic neurosurgery.

This booklet is dedicated to him in profound grief with grateful thanks and infinite respect.

Historical background

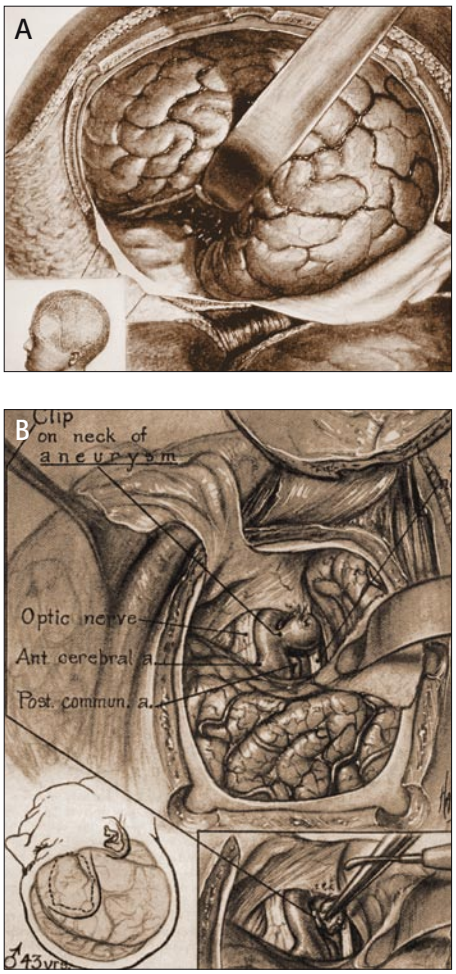

Fig. 1 *Frontolateral craniotomy approaching the central skull base as reported by Walter Dandy in 1922 (A). Note the extensive and wide-ranging exploration of the cortical surface to achieve visual and surgical control; to obtain access to a suprasellar lesion, the left optic nerve was sacrificed. In 1938, Dandy demonstrated a significantly limited skin incision and cranial opening when operating on an aneurysm of the right carotid artery (B). The illustration demonstrates Dandy's obvious learning process in reducing approach-related surgical trauma.*

At the beginning of the 20th century, neurosurgical procedures were performed using large sized craniotomies. At that time, such large approaches were necessary for several reasons. Firstly, because of the simple diagnostic techniques available at the time, the size and site of pathological lesions could not be accurately determined before surgery; therefore, the craniotomy had to be large enough to find the lesion within the intracranial space. Secondly, illumination in operating theatres was poor and the cranial opening had to be large enough to bring light into the surgical field. Thirdly, instruments at that time were not designed for neurosurgery but for general surgery and they were too large to be used within narrow openings. In addition, neurosurgical teams consisted of at least three members, thus, six hands and their large instruments obscured the surgical field and the craniotomy had to be large enough to allow sufficient observation of the site (Fig. 1A).

Nevertheless, technical developments in neurosurgical therapy allowed a marked reduction in operative, approach-related traumatisation (Fig. 1B).

The first important factor in surgical refinement was a diagnostic one. In 1918, radiographic techniques were introduced into neurosurgery by Walter Dandy. With the help of air injection and fluoroscopy, he was able to demonstrate the ventricular system. An additional achievement was made in 1927 when Edgar Moniz described the technique of cerebral angiography. However, ventriculography and angiography allowed only an indirect observation of brain tissue while recording deformed and displaced ventricles and vessels (Fig. 2).

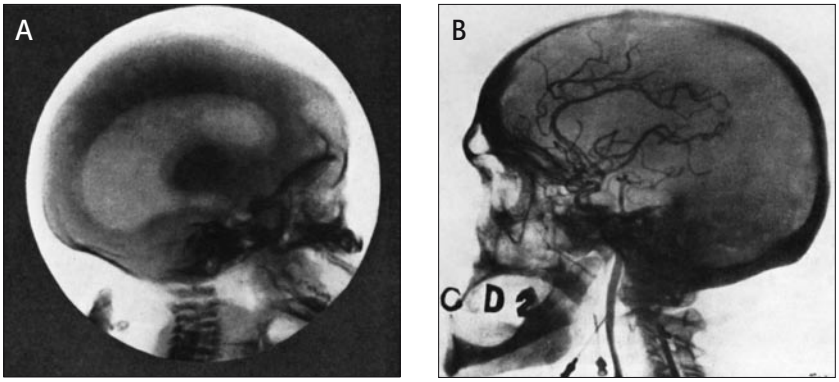

Fig. 2 *Milestones in cerebral imaging. Ventriculogram of a child suffering from severe hydrocephalus published by Dandy in 1913 in his paper entitled "Ventriculography following the injection of air into the cerebral ventricles" (A). In 1927, Moniz published in his article "Arterial encephalography, its importance in the localization of cerebral tumors" the network of the internal carotid artery in 20-year-old men (B).*

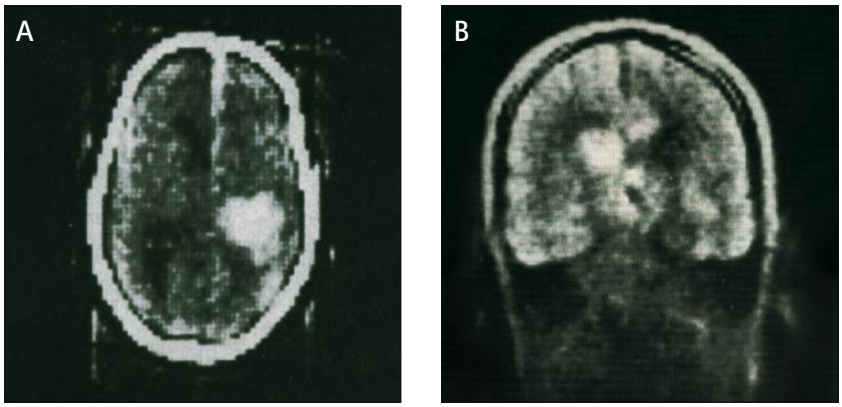

Fig. 3 *One of the first CT scans published by Hounsfield in his article "Computerized transverse axial scanning tomography" in 1973 showing displacement of the ventricles according to a space occupying bleeding of the left basal ganglia (A). An early coronar MRI scan of a craniopharyngioma from the Nottingham facility in 1980 (B).*

The first real and direct visualisation of the cerebrum was provided by "computerized axial tomography" (CT) described by Hounsfield and Ambrose in the early 1970's. Since the 1990's, magnetic resonance imaging (MRI) has enabled the accurate determination of topographic relationships of specific lesions to individual anatomical structures. These methods of preoperative imaging allow the exact preoperative evaluation of the individual pathoanatomical situation thus enabling a precise planning of the surgical intervention (Fig. 3).

The second important factor in the evolution of neurosurgical techniques was an optical one: the development of intraoperative illumination devices. Writing about the pioneering time of neurosurgery, Paul C. Bucy described a surgical procedure of Otfried Foerster in the early 1930's *„...the scene was a primitive one. The only source of illumination of the operating field was a student lamp with a brass reflector. It was held in my hand, which soon became unsteady much to Foerster's disgust"* (Fig. 4). Nevertheless, the use of special surgical reflectors and head mounted lamps in operating theatres allowed more precise visualization and manipulation within the deep-seated surgical field (Fig. 5).

Fig. 4 *Photograph showing Otfried Foerster undertaking cranial surgery in the autumn of 1930. Note Paul C. Bucy in street clothes holding a student lamp.*

Fig. 5 *Harvey Cushing's transnasal approach to pituitary tumors using a head-mounted lamp .*

Fig. 6 *The real pioneer of microneurosurgical techniques, M. Gazi Yasargil, during a microsurgical procedure in the University Hospital Zurich.*

Fig. 7 *An intensely concentrated Axel Perneczky operating during a minimally invasive endoscopic procedure in the Neurosurgical Department of the University Hospital in Mainz.*

However, the real revolution in illumination was the use of operating microscopes, which enabled inauguration of the microsurgical area in the 1960's and early 1970's. Dwight Parkinson pointed out very clearly the advantages of this new device: *"Early in 1960 the neurosurgical section borrowed an operative microscope from the otolaryngology department. The microscope provided us with the enormous advantages of coaxial illumination, magnification, and simultaneous viewing for the surgeon and resident"*. As chairman of the University Hospital in Zurich from 1973 to 1992, M. Gazi Yasargil became the leader of microneurosurgical techniques worldwide (Fig. 6). A further milestone in the evolution of intraoperative visualization was the introduction of endoscopes during neurosurgical procedures: the birth of minimal invasive neurosurgery under the encouraging leadership of Axel Perneczky (Fig. 7).

The third important factor in further development was a technical one: the invention of adequate microsurgical instruments. The technique of bipolar coagulation was adopted for microsurgery by James Greenwood and Leonard Malis and fine microinstruments were developed for intracranial use.

However, despite the above-mentioned development of preoperative diagnostics, illumination devices, and neurosurgical instruments, cranial neurosurgery was still characterized in the 1980's and 1990's and often also recently by large, extended craniotomies.

Nevertheless, unnecessary exploration may cause involuntary injury to the delicate cortical surface. In order to gain an impression of dimensions of a potential cortical trauma by extended surgical approaches, the simple equation $r^2 \times \pi$ can be used to calculate the exposed surface. During a conventional craniotomy with a bone flap diameter of approximately 8 cm, the area of exposed brain area is: $r^2 \times \pi = 4\ cm^2 \times \pi = 50.27\ cm^2$. The area of exploration during keyhole craniotomy with a 2 cm diameter is: $r^2 \times \pi = 1\ cm^2 \times \pi = 3.14\ cm^2$. We can see that in choosing a limited "keyhole"-like approach, it is possible to reduce cortical exploration and injury with distinctly less damage to neural tissue.

The real pioneer of keyhole neurosurgery was Axel Perneczky. As Chairman of the Neurosurgical Department in Mainz, Germany, he consequently developed the concept of minimally invasive and endoscope-assisted neurosurgery.

Concept of Minimally Invasive Keyhole Neurosurgery

The aim of minimally invasive neurosurgery is not to harm the patient by creating a tailormade limited less traumatic approach based on skilled preoperative planning and detailed neuroanatomical and neurofunctional knowledge.

Using modern diagnostic tools, the specific anatomy and pathology of the individual patient can be precisely visualized and anatomical pathways and surgical corridors determined for optimal surgical access. According to the predefined access, surgical dissection can be subsequently performed creating a much less traumatic cranial opening.

Note this basic message: the aim is not the limited cranial opening, but the limited approach associated traumatization with less brain exploration and retraction! The craniotomy should be as small as possible for minimally invasive exposure, but as large as necessary for achieving maximal surgical effect. In this way, limited exposure is not the primary goal but the result of the keyhole concept with the main and most important goal being to avoid surgery-related complications.

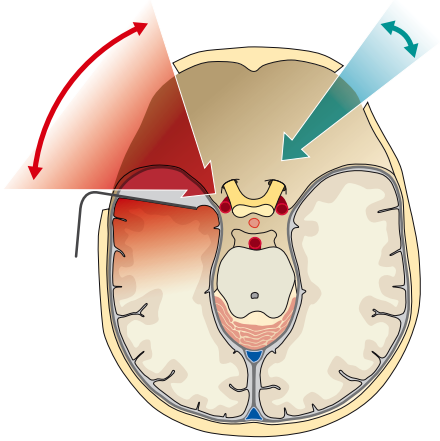

Fig. 8 *Schematic drawing comparing the large sized standard (red) and minimally invasive keyhole exposure (green). Using the limited approach, the surgical corridor is predefined and cannot be changed during surgery. Distinguished preoperative approach planning and self-made "skin-to-skin" performance of the procedure are preconditions for keyhole neurosurgery.*

Critical aspects of keyhole approaches

The clear benefit of keyhole neurosurgery is the minimal approach-related traumatization. However, small craniotomies offer some important restrictions which should also be considered critically (Tab I). The major limitations of keyhole approaches are:

1. limited and predefined surgical corridor,
2. difficult intraoperative orientation,
3. insufficiency of available microinstruments and
4. decreased illumination in the deep-seated field.

(1) Performing a keyhole craniotomy, the surgical corridor is predefined and cannot easily be changed during the procedure. Therefore, the craniotomy must be placed exactly to avoid intraoperative difficulties or disorientation. Two preconditions of a precisely placed craniotomy are important: 1. distinguished preoperative approach planning and 2. personal self-made performance of the surgery by the senior surgeon himself. Note that this personal "skin to skin" performance should include positioning of the patient, skin incision, craniotomy, and surgical exposure of the target region. This specific and individual self-made surgery is a central question in keyhole

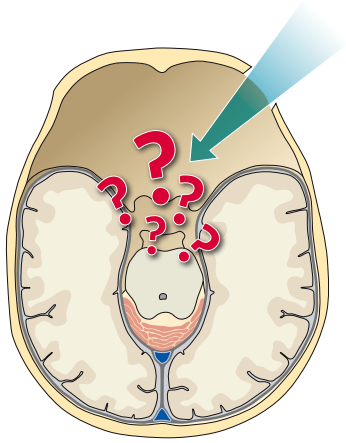

Fig. 9 *Limited craniotomy complicates surgical orientation. Intraoperative use of navigation devices and real-time imaging can increase operative safety.*

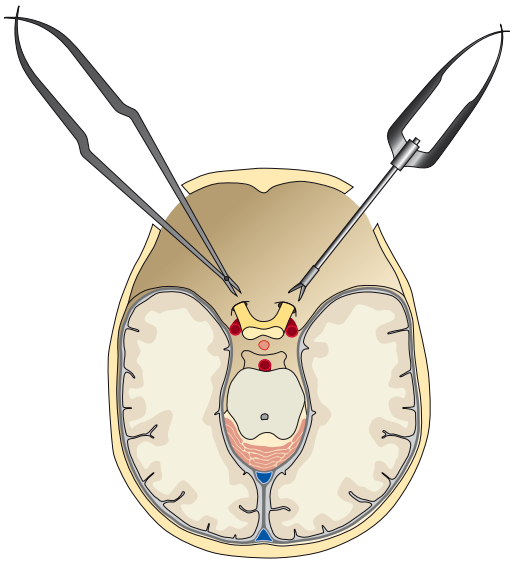

Fig. 10 *Keyhole approach handicaps the use of conventional microinstruments. In comparison, tube-shaft designed instruments allow unhindered manipulation, even if the craniotomy is smaller than 1.5 cm.*

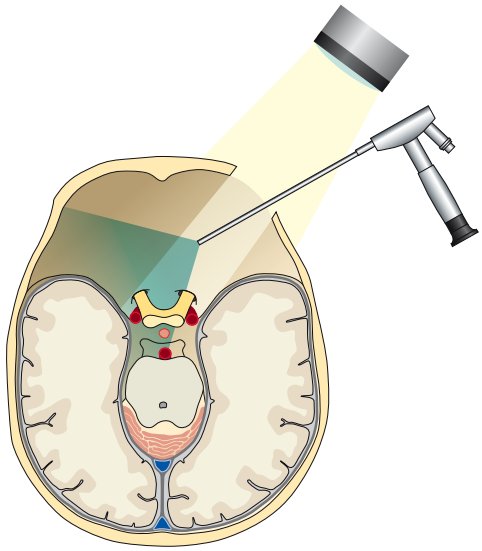

Fig. 11 *Limited approaches cause significantly reduced visual control in the deep-seated surgical field. Endoscope-assisted TEAM technique offers safe and effective visualisation, even in hidden parts of the site.*

neurosurgery. In this way, the principle of the tailored minimally invasive keyhole neurosurgery is in direct contrast to a standard surgical intervention via extended approaches (Fig. 8).

(2) The second drawback of keyhole procedures is the difficult intraoperative orientation. The intraoperative use of navigation systems and real-time imaging e.g. ultrasound, intraoperative CT and MRI may be helpful if the limited cranial opening leads to a confusing and purely overviewed situation (Fig. 9). Nevertheless, these technical tools can never replace the precise preparation and particular patho-anatomical knowledge of the target region!

(3) The narrow viewing angle and almost coaxial control of dissection causes an additional problem. In our experience, if the craniotomy is smaller than 15 mm, the intraoperative use of conventional microinstruments becomes very limited. For this reason, the development and intraoperative use of novel microinstruments, e.g. scissors, grasping and coagulating forceps, clip appliers etc. is mandatory for such key-hole surgery. In particular, slim, tube-shaft designed tools allow unhindered manipulation even through limited keyhole craniotomies (Fig. 10).

(4) The fourth and probably main difficulty of keyhole approaches is the loss of intraoperative light and sight through the limited craniotomy causing significantly reduced optical control during surgery. However, the neurosurgeon must be able to recognise both normal anatomical structures to save them and abnormal structures to resect them. For the purpose of bringing light into the surgical field and controlling manipulation deep inside the operating field, surgical microscopes can be effectively supported by the optical properties of modern endoscopes (Fig. 11). Advantages of endoscopes are: 1) increased light intensity, 2) extended viewing angle and 3) clear depiction of details in close-up.

In this publication we have termed the combined TEAM-work of microscope and endoscope as **T**ranscranial **E**ndoscope-**A**ssisted **M**icroneurosurgery.

Modern video equipment provides excellent image quality. The endoscopic video signal is recorded and displayed on a video monitor, which should be ideally placed in front of the surgeon. Recently, developments in camera design have enabled neurosurgeons to use full high definition (HD) technology in the operating theatre. The brilliant image quality offers exact and clear depiction of the smallest details within the surgical field resulting in improved surgical orientation and safety.

Table I. Mimimally Invasive Key Hole Approaches

Limitations	Solutions
Predefined corridor	Approach planning Tailored craniotomy "Skin to skin" personal performance
Difficult orientation	Neuronavigation Intraoperative imaging
Narrow corridor	Tube-shaft instruments
Decreased visualization	Endoscope-assisted TEAM-technique

Personnel, operating room ergonomics, and instrumentation for minimally invasive keyhole neurosurgery

Operating theatre personnel

Operating theatre personnel play an essential role in performing minimally invasive keyhole procedures. The proper education and training of surgical assistants, nurses, and technical assistants are mandatory for safe intraoperative care.

Operating theatre layout

Today's neurosurgical operating theatres must be large enough to accommodate the patient, the operating personnel, and highly sophisticated neurosurgical equipment (Fig. 12).

The patient is brought on the operating table according to the target region and surgical positioning. In the majority of cases, the surgeon stands directly at the head with his assistant on the left side. The scrub nurse sits or stands directly by the side of the surgeon, allowing precise assistance. The anesthesiologist with his equipment is at the foot end of the patient. It is important for the surgeon to have enough elbowroom for frequent changes in direction of the viewing angle. In our opinion this "dancing around the table" can be performed in a more relaxed manner if the surgeon stands during the procedure.

Fig. 12A *The BrainSUITE®, a highly sophisticated operating room for TEAM neurosurgery with integrated intraoperative CT and Neuronavigation in the Centre for Endoscopic and Minimally Invasive Neurosurgery (Hirslanden Hospital Zurich, Switzerland).*

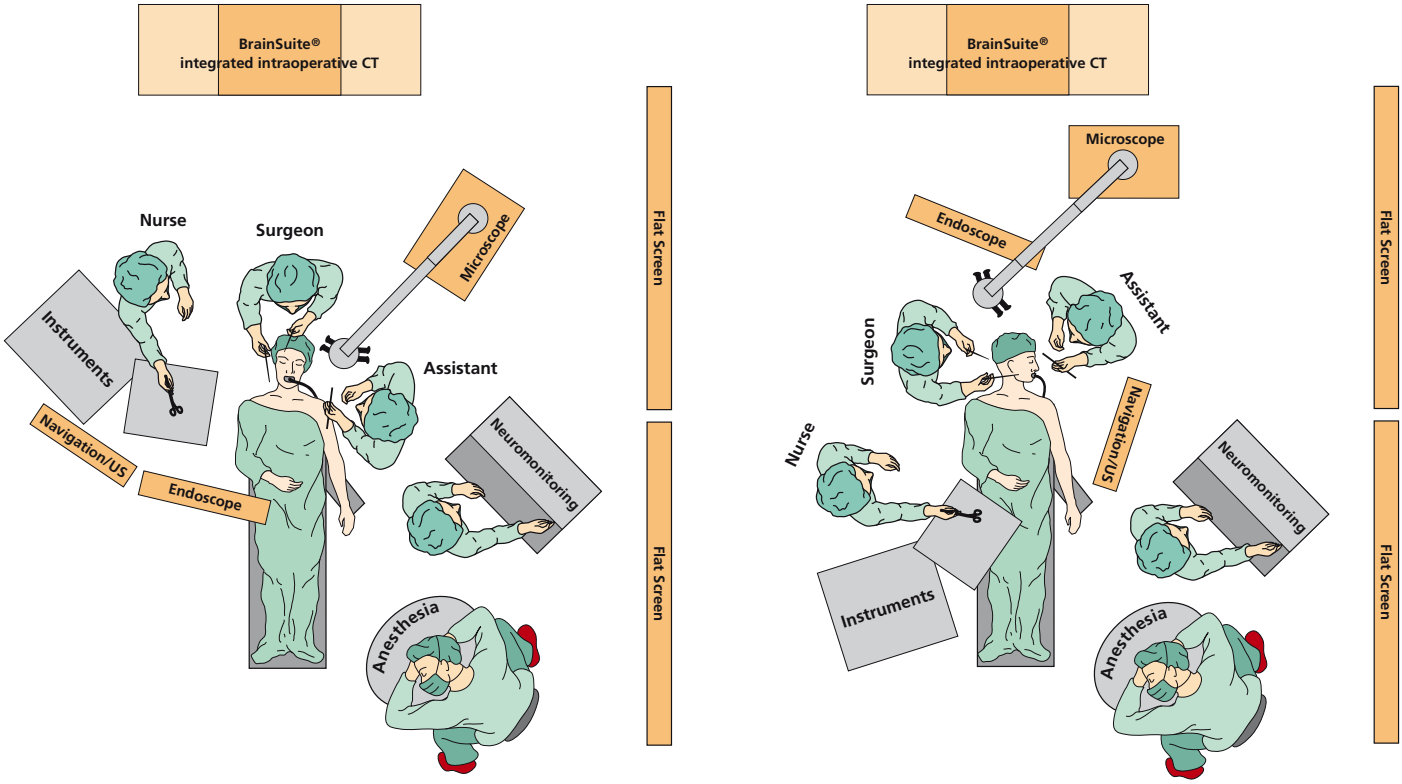

Fig. 12B *Schematic drawings, illustrating operating theatre layout during supraorbital (left) and retrosigmoidal (right) craniotomy in supine position. Intraoperative ergonomics plays an important role in minimally invasive neurosurgery with sensitive interplay between microsurgical and endoscopic instrumentation.*

In most keyhole approaches, the microscope is to the surgeon's left and the video monitor is in such a position that the nurse and the anesthesiologist can both follow the procedure. If used, the monitor for endoscopic visualisation, navigation is placed directly in front of the surgeon. Frequently, additional equipment is also used during keyhole surgery. Intraoperative CT or MR-scan, and ultrasound are used in several tumor cases and Doppler-sonography and digital C-arm fluoroscopy in neurovascular surgery. However, the relationship between the neurosurgeon's position and that of the patient is delicate and often impaired during surgery. The large number of highly sophisticated tools should not hamper efficiency in the operating theatre.

The operating microscope, intraoperative use of endoscopes

The intraoperative use of microscopes is mandatory in keyhole neurosurgery. The operating microscope provides both stereoscopic magnification of the operative field and illumination of the surgical field. However, as mentioned above, the loss of light intensity in the depth of the surgical field is a fundamental problem. For the purpose of bringing light into the site, operating microscopes can effectively be combined with the intraoperative use of modern endoscopes (Fig. 13).

The advantages of the endoscopic image are the increased light, extended viewing angle and a better depiction of anatomical details in close-up. The endoscope is especially ideal for obtaining a detailed view of structures in the shadow of the microscope's light beam. Thus, in situations during microsurgical dissection where additional visual information of the target area is desired or when avoidance of retraction of superficial structures is recommended, an endoscope may be introduced into the surgical site. Both devices, microscope and endoscope, complement each other in a TEAMwork due to their different optical properties (Fig. 14).

For endoscope-assisted microsurgery, rigid lens scopes are recommended because only instruments with rigid shafts can be controlled precisely and because, at least at present, only lens scopes offer acceptable image quality. Endoscopes with angled shafts are preferred for endoscope assisted neurosurgery as the camera attached to the eyepiece does not interfere with the visual field of the microscope and does not hinder surgical manipulation (Fig. 15). Different degrees of angulation of the front lens offer viewing angles of 0°, 30°, 45°, and 70°. In addition, modern high quality video technology is necessary to achieve full use of endoscope-assisted microsurgery.

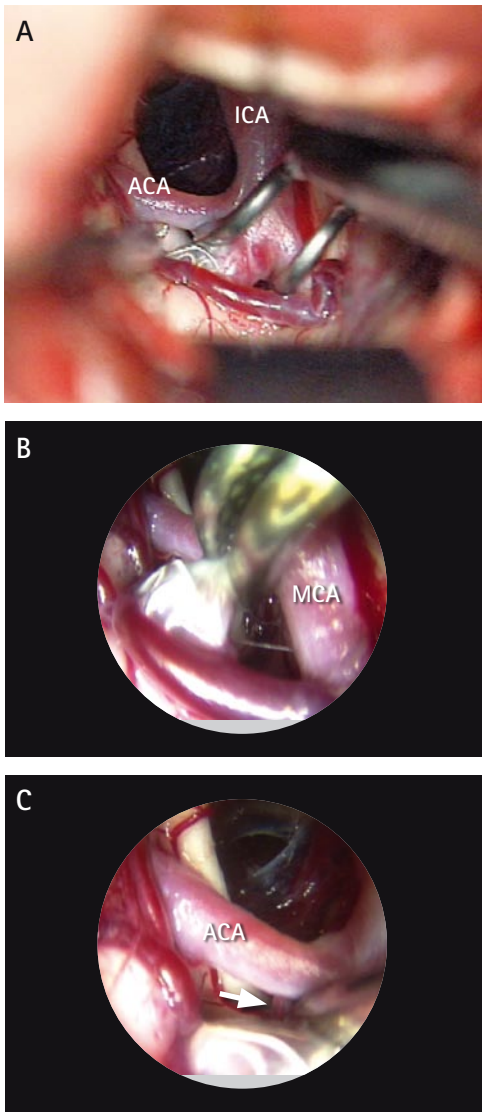

Fig. 13 *Clipping of a precoiled aneurysm of the carotid bifurcation through a right sided supraorbital keyhole carniotomy (A). Endoscopic investigation verifies complete closure of the aneurysm (B). In a close-up position safe control of the untouched perforator vessel can be realised in the shadow of microscope light beam (arrow). The ACA is not narrowed according optimal clip placement (C).*

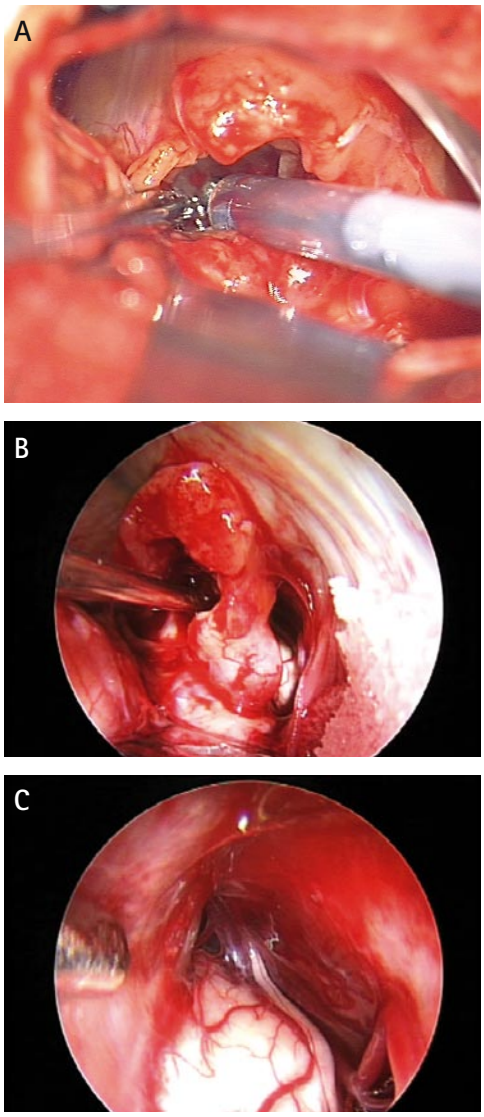

Fig. 14 *Simultaneous use of the microscope and endoscope according to the TEAM technique in vestibular schwannoma surgery. After microsurgical enucleation of the tumor (A), the endoscope is used for additional visual control within the cerebellopontine ange (B). Behind the tumor in the shadow of the microscope's light beam, the abducent nerve, pons, and the facial nerve can be seen (C). Note the ergonomic design of the special angled endoscope: the angles shaft does not interfere with the visual field of the microscope and does not hinder surgical manipulation (D).*

Fig. 15 *Rigid lens endoscopes with 4mm diameter and 0°, 30° and 70° viewing angles for endoscopic visualization during microsurgical procedures. The sophisticated angled design allows free surgical manipulation around and along the endoscope.*

Fig. 16 *A full HD camera unit allowing brilliant image quality in endoscopic neurosurgery. Superior visualization is particularly important in neurosurgery, thus differentiating subtle intracranial structures. However, it is important to note that HD visualization with enormous optical resolution requires optimal illumination of the surgical field using the halogen light source and premium light cable.*

Fig. 18 *The digital EDDY system provides rapid and user-friendly video documentation of the endoscopic procedure.*

Fig. 17 *Axel 180 Halogen light source and light cable.*

Fig. 19 *Complete endoscopic equipment with highly-sophisticated flat screen monitor, full HD-camera unit, halogen light source and EDDY digital documentation tool.*

Recently, the intraoperative use of full high definition (HD) image quality offers a new area in endoscopic neurosurgery with an increased range of indications in minimally invasive neurosurgery (Fig. 16). The image quality of the full-HD system is markedly superior to that of a standard one- or three-chip camera unit providing a five times higher optical resolution. This superior quality is particularly important in delicate situations, namely the differentiation of subtle structures and in the case of blurred scope vision.

However, this enormous optical resolution needs optimal illumination of the field: high power xenon sources with cold light and ideal light cables are important for this reason (Fig. 17).

A recording system is also an important part of the equipment for documentation of the procedure, which is useful for scientific evaluation and teaching purposes. An ideal solution is a digital video system allowing user friendly and rapid recording (Fig. 18).

The use of TEAM technology in the course of microsurgical procedures with significantly improved visual control may contribute to the criteria of the keyhole concept with minimum iatrogenic trauma and maximum efficiency.

Microsurgical instruments

The use of microneurosurgical instruments is obligatory in treating intracranial lesions. Highly sophisticated instrumentation including microdrills, Kerrison micropunches, self-retaining retractors, suction tubes, fine bipolar forceps, microscissors, diamond knives, microforceps, microdissectors, microcurettes, and clip appliers are mandatory for microsurgical dissection.

Nevertheless, when approaching deep-seated areas through a limited craniotomy with a diameter of ca. 15 mm, the intraoperative use of conventional microinstruments may be a problem because of the narrow surgical corridor. For example, a bipolar forceps or a microscissor will be closed at its tip when the target is reached because the arms have already been pressed together by the edges of the small skull opening (Fig. 20).

Slender keyhole microinstruments have been specially created allowing unhindered introduction of the tool through the limited craniotomy (Fig. 21). These tube-shaft designed instruments can be used in a much reduced operating corridor enabling safe manipulation within the narrow surgical passage and obvious visualization of the surgical field. By noticing that usually only the last 2-3 millimetres of a scissor blade are actually used, their blade size was hence reduced producing improved vision, range of motion and access.

In several cases, the application of tube-shaft micro-instruments is obligatory when operating through keyhole approaches (Fig. 22).

The delicate keyhole instruments should be carefully cleaned at the end of the operation, protecting sharp tips, and kept in special trays that separate the different types of instruments. Careful handling by the operating theatre staff can eliminate the wear and tear of sensitive microdevices.

Bitte Bild von Neuroendoskopie-Katalog Seite 25, rechts

Fig. 20 *Slim, responsive "pivot point" bipolar forceps, especially developed for TEAM technique. The special pin between the branches opens the tip of the forceps by additional compression of the handle – a must-have instrument by keyhole neurosurgery, operating through narrow surgical corridors.*

Fig. 21 *Comparison of a conventional bayonet-designed clip applying forceps to a special tube-shaft instrument, expressly developed for minimally invasive keyhole surgery. When operating through limited craniotomies, the use of slim tube-shaft equipment is often obligatory for safe and unhindered manipulation in the narrow surgical field.*

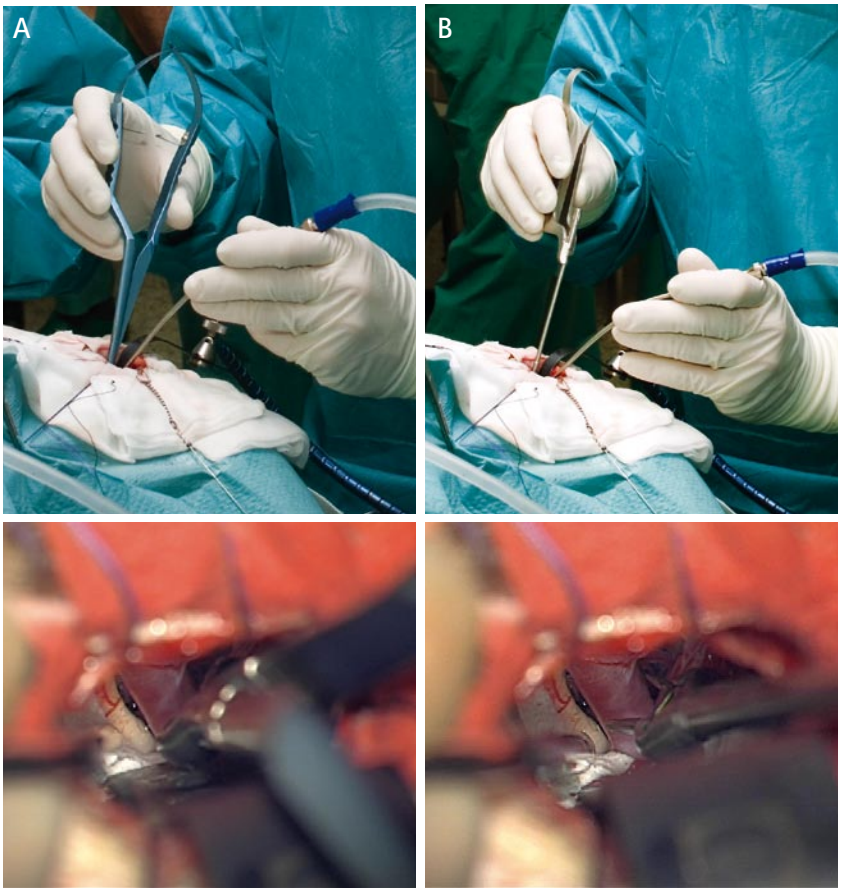

Fig. 22 *Aneurysm clipping through supraorbital keyhole craniotomy. Note that the conventional clip applier requires significantly more space within the limited operative corridor! The keyhole approach handicaps the use of the applier and the clip is hidden within the forceps, its placement cannot be controlled (A). The tube-shaft designed instrument can perfectly be used in the keyhole approach without limitation in surgical manipulation and obvious visualization of the field; the clip is well seen within the jaws of the applier, thus allowing safe control of aneurysm closure (B).*

General techniques and performance of endoscope-assisted minimally invasive keyhole approaches

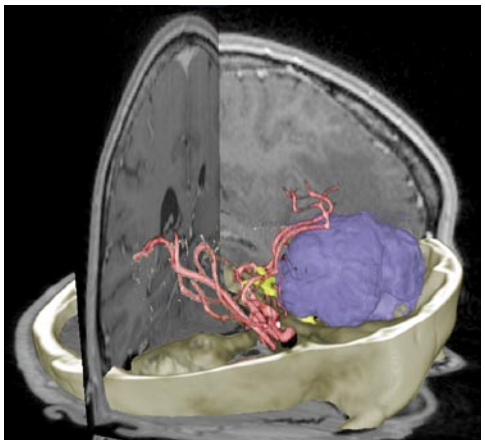

Fig. 23 *Three-dimensional reconstruction of a large olfactory groove meningioma (blue) in the virtual reality workstation. Note compression of the optic nerves (yellow) and displacement of the anterior cerebral arteries (red). After precise planning of the suitable approach, the tumor could be removed through a limited supraorbital craniotomy.*

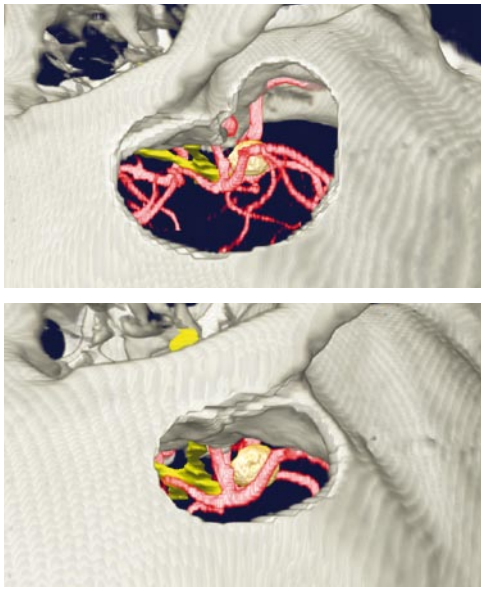

Fig. 24 *Previously coiled aneurysm of the right internal carotid artery, virtually observed through a pterional (A) and supraorbital (B) approach using the Dextroscope planning tool. In the virtual reality, both approaches were considered and compared. Note the frontolateral pterional approach: the MCA within the Sylvian fissure obscures the view. Therefore, opening the fissure and temporal retraction is necessary for approaching the aneurysm. In comparison, the supraorbital subfrontal craniotomy offers unhindered visualization and safe proximal control (courtesy of Ralf Kockro, University Hospital Zurich, Switzerland and Eicke Schwandt, Neurosurgical Department Mainz, Germany).*

Preoperative planning

The goal of the preoperative planning is to choose the best and most accurate surgical access leading to a minimum of iatrogenic trauma and achieving a maximum of surgical efficiency without missing the target or causing injury to sensitive intracranial structures.

By choosing the best approach to a specific lesion, the size of the craniotomy can be dramatically reduced with the need for only a small dura opening, with less brain exposure and retraction. These advantages of minimally invasive keyhole microsurgery may contribute to improved postoperative results including shorter hospitalisation time because of reduction in the risk of complications such as bleeding or re-bleeding with neurological deterioration, epileptic seizures, leakage of cerebrospinal fluid, infection, scarification, and cosmetic impairment.

In this way, precise planning of the approach plays a critical role in performing minimally invasive keyhole surgery. The smaller the craniotomy, the greater the need for precise planning because the surgical corridor cannot be changed during the procedure. The preoperative planning is based on accurate anatomical knowledge of the target region and a careful preoperative analysis of diagnostic images. Not only is the diagnosis of principle interest. The task of modern neuroradiology should not end with the definition of the suspected pathology but more to determine anatomical corridors of the subarachnoidal spaces that provide access to the pathological processes. These anatomical paths for surgical dissection should be described preoperatively and be included in the planning of the surgical procedure.

Computer technology is being used increasingly to help surgeons analyze preoperative imaging data. Various programs have been developed to generate three-dimensional models in order to plan surgical approaches in a more realistic way (Fig. 23). Conceptually, the planning of a surgical procedure with three-dimensional computer generated data should reflect the three-dimensionality of the real procedure. Especially helpful is the use of stereoscopic displays and virtual manipulation with appropriate tools. This would allow generation of a comprehensive three-dimensional scenario which can then be used to understand the spatial form and extent of the lesion and to define the ideal surgical corridor leading to it. The technology to achieve this lies within the realm of what has been called „Virtual Reality" and it implies 1) stereoscopic display of the data and 2) manipulation with 3D tools instead of mouse and keyboard. Over the past years, we have been using the system "Dextroscope" (Volume Interactions Pte. Ltd., Singapore) to plan a variety of neurosurgical procedures in this way (Fig. 24).

Transcranial Endoscope-Assisted Microneurosurgery (TEAM)

Patient positioning

In minimally invasive keyhole procedures, the senior neurosurgeon himself must plan and perform the proper positioning of the patient before starting the surgical procedure. The goal of patient positioning is to achieve optimal surgical access to the target region without endangering the patient. In addition, the position should offer ergonomic conditions for the surgeon and make the operation physiologically acceptable during the often long, time consuming procedures. The use of a modern, electric operating table also facilitates optimal patient positioning during surgery.

Orientation according to anatomical landmarks

After preoperative planning of the approach according to the individual pathoanatomical situation and after patient positioning according to the target region, the placement and size of the craniotomy should be individually tailored.

For this reason, visible and palpable structures of the patient's anatomical landmarks should be determined and drawn on the skin. Special attention must be given to the cranial musculature and to the course of superficial neurovascular structures. Only thereafter should the borders of the craniotomy be delineated, taking into consideration the position of the lesion and the landmarks. After defining the craniotomy, the individual skin incision is determined (Fig. 25).

The optimal placement of the craniotomy can be effectively monitored with the use of modern navigation systems. However, the approach must be determined after surgical orientation according to the accurate anatomical knowledge and the navigation device should basically be used only as a precise control tool (Fig. 25 D).

Skin incision and soft tissue dissection

The skin incision is made according to the preoperative planning and anatomical orientation. Soft tissue dissection should offer adequate inspection of the osseous surface while minimising approach-related trauma. An additional important factor is to achieve cosmetically favorable postoperative results with subsequent satisfaction among patients.

Craniotomy and dural opening

As mentioned above, the aim of keyhole neurosurgery is not just the limited craniotomy but the limited brain exploration and minimal brain retraction. Thus a limited craniotomy is not the goal but the result of the philosophy of minimal invasiveness in neurosurgery. The craniotomy and dural opening should be as small as possible to offer minimal brain trauma, although as large as necessary to achieve a safe surgical dissection. The greatest mistake is to create a far too small craniotomy with loss of essential surgical control!

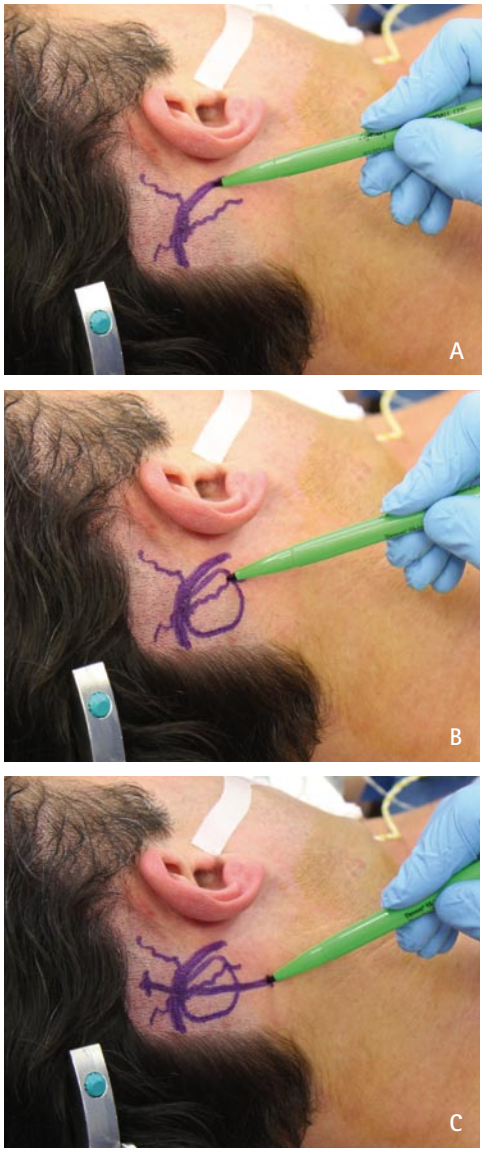

Fig. 25 *Planning of a right sided retrosigmoidal craniotomy. As a first step, important anatomical landmarks of the lateral suboccipital area, e.g. sutures and the course of the sigmoid sinus are identified (A). As second step, the borders of the craniotomy are marked, taking into consideration the position of the lesion and landmarks drawn on the skin (B). Only thereafter, the individual optimum line of the skin incision is defined (C). Note the three steps: anatomy – craniotomy – skin incision.*

Fig. 25D *The optimal placement of the craniotomy can be effectively controlled with the use of neuronavigation (BrainLAB, Feldkirchen, Germany). However, note the basic principle: the approach must be defined according to anatomical landmarks and the navigation should be used only as a precise control tool.*

Fig. 26 *TEAM work of microscope and endoscope in minimally invasive keyhole neurosurgery.*

Intradural dissection

The dural opening should offer optimal intracranial exposure and facilitate the post-operative closure. The intracranial dissection should be performed after exact planning of every step of the procedure. The surgeon should be able to "run through" each step of the operation in his or her mind according to mandatory anatomical and surgical experience. This offers safe manipulation within the surgical field and will help to prevent intraoperative complications.

In order to combine minimally invasive microsurgery with endoscopic techniques according to the TEAM concept (Figs. 26, 27), two different means of using endoscopes in cranial microsurgery are available.

Endoscope-assisted microneurosurgery (EAM) offers endoscopic visualization of the surgical field during a keyhole procedure. For immediate visual control of surgical dissection, the surgeon introduces the endoscope "freehand" into the site: the endoscope is held in one hand, instruments in the other hand. Typical indications are 1) short anatomical orientation during impaired intraoperative overview; 2) observation of hidden parts of the field; 3) verification of effect in surgical dissection, e.g. precise tumor removal or clip application. In most cases, the "one-handed" surgeon uses the endoscope only for a short time during surgery as the instrument is mainly a tool for visual assistance. Only simple manipulations can be performed with this technique (Fig. 27A).

Endoscope-controlled microneursurgery (ECM) is a technique where the endoscope is fixed by a special holding device within the surgical corridor offering bi-manual dissection under a solely endoscopic image. In this way,

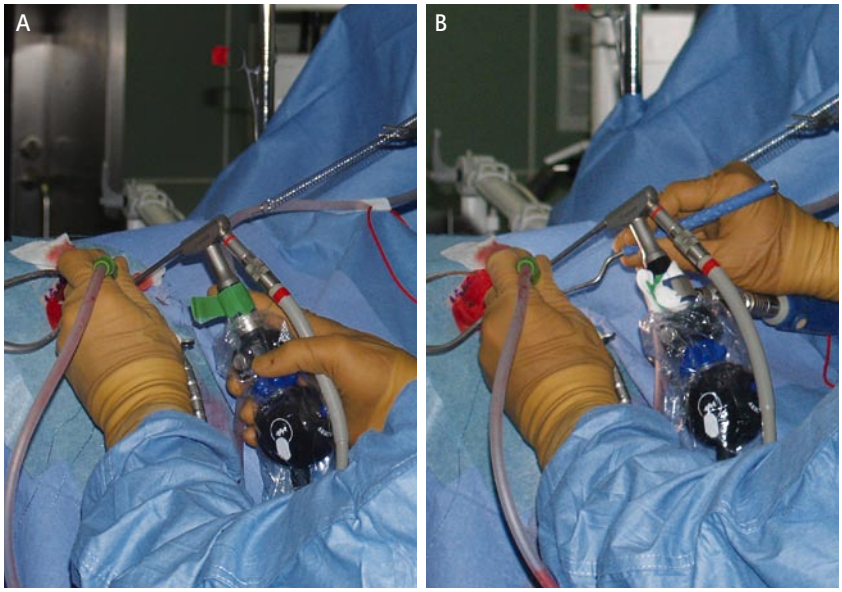

Fig. 27 *Intraoperative use of the angled endoscope, operating through right-sided retrosigmoidal craniotomy. For anatomical orientation and observation of hidden parts of the field, the endoscope is used in a free-hand technique; the surgeon holds the endoscope in the right hand, in the left hand is the sucker for cleaning the field (A). With fixation of the endoscope in holding device, the surgeon is able to dissect with both hands without using surgical microscope (B). Note the bayonet-designed microinstrument with ergonomic grab handle for well-balanced weight distribution and a perfect grip.*

the surgeon is able to use both hands to manipulate without limitation in surgical dissection. A typical indication is the removal of tumor remnants in hidden parts of the field. Using this technique, the endoscope is used permanently for a longer time during keyhole surgery without a microscope (Fig. 27B).

Wound closure

After finishing the intracranial procedure, the subarachnoid space is filled with artificial CSF at body temperature. The dural incision is closed, preferably watertight, using either interrupted or continuous sutures. If tension has developed in the dural plane, a piece of muscle can be sutured into the dural closure. The bone flap is fixed with a titanium Craniofix miniplate or similar technique. Usually one or two plates are enough to allow sufficient fixation; if possible, the plate should close the burr hole trephination. Note that the bone flap should be fixed tightly to achieve optimal cosmetic results. After final verification of hemostasis, the muscle and subcutaneous layers are closed with interrupted sutures. For closure of the skin, different techniques can be used. On account of the limited skin incision and non-traumatic surgical technique in keyhole neurosurgery, a suction drain is usually not required.

The supraorbital keyhole approach

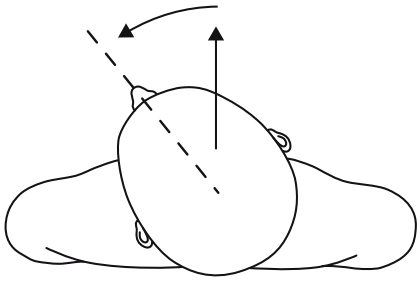

Fig. 28 *Patients supine position for surpraorbital craniotomy. The head is elevated and retroflected for gravity supported subfrontal dissection. Degree of rotation depends of the target region.*

Patients preparation

When creating a supraorbital keyhole, the patient is placed supine on the operating table with the head fixed in a three-pin Mayfield head holder. Initially, the head is elevated above the level of the thorax to decrease intracranial tension. A retroflexion of about 15° supports gravity-related self-retraction of the frontal lobe and head rotation offers ergonomic intracranial dissection (Fig. 28). The degree of exact rotation depends on the target region: for exploration of the middle cerebral artery within the ipsilateral Sylvian fissure, 15° rotation is recommended. For the lateral suprasellar area 30°, for the anterior communicating region 45° and for the olfactory groove, ca. 60° turning of the head is sufficient.

After patient positioning, the important anatomical key-point landmarks of the frontal area such as the orbital rim, supraorbital foramen, temporal line, level of the frontal cranial base, impression of the Sylvian fissure and the zygomatic arch should be determined precisely. Special attention should be given to the course of the superficial neurovascular structures of the fronto-temporal region such as the supraorbital nerves and artery, and the frontal branch of the facial nerve. After identification of these landmarks, exact placement of the craniotomy is defined and, if used, controlled with the navigation device. Only thereafter is the correct line of the eyebrow skin incision marked with the sterile pen (Fig. 29).

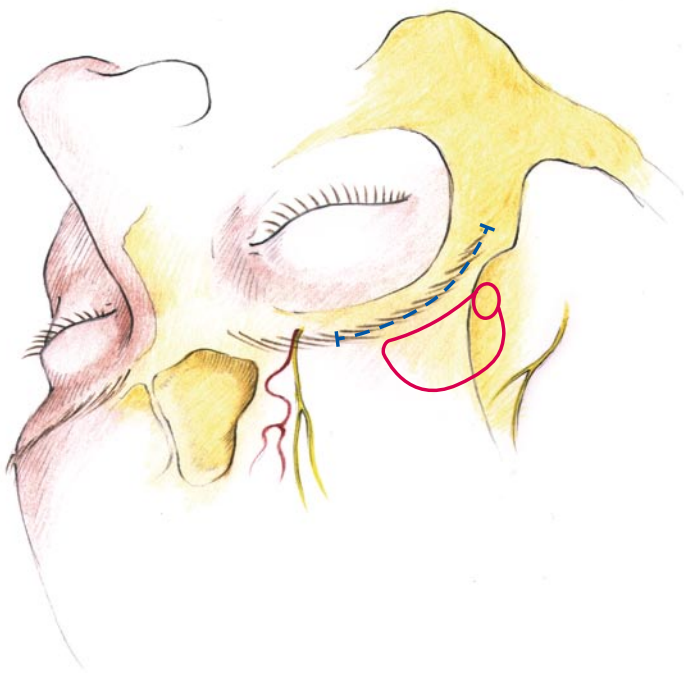

Fig. 29 *Photograph and schematic illustration demonstrating important anatomical landmarks of the frontal – supraorbital region. After identification of these landmarks, borders of the craniotomy are marked and exact skin incision precisely defined.*

Surgical technique

Step 1. The skin incision is started laterally from the supraorbital incisura within the eyebrow. To achieve a cosmetically optimal result, the incision should follow the orbital rim. Note that the skin incision should not extend medially to the supraorbital nerve to avoid frontal numbness; the frontal branch of the facial nerve and the superficial temporal artery never cross this type of skin incision (Fig. 30).

Step 2. The skin flap is dissected with scissors in the frontal direction to achieve optimal supraorbital exposure. Manipulation in the orbital way is unnecessary and should be restricted to a necessary minimum, thus avoiding postoperative periorbital swelling. Note protection of the sensitive skin (Fig 31).

Step 3. The frontal skin flap is retracted with holding sutures. The frontal muscle is then cut with a monopolar knife in a medial to lateral direction. As a rule of the thumb, this incision should be performed ca. 2 cm over the orbital rim (Fig. 32).

Step 4. As the temporal line is reached with the monopolar, its blade is turned 90° to temporal. The cutting then follows the temporal line in basal direction; in this way, the frontozygomatic part of the temporalis muscle is minimally stripped from the bony insertion (Fig. 33).

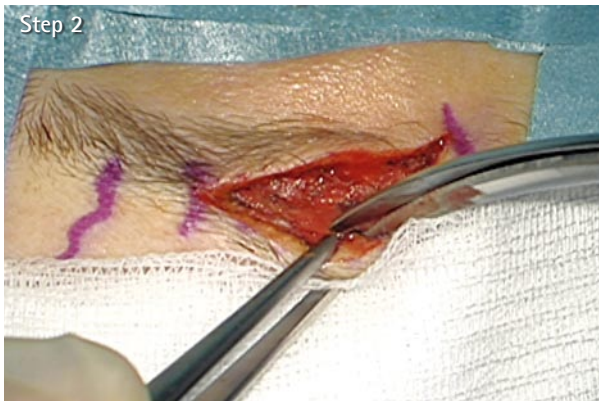

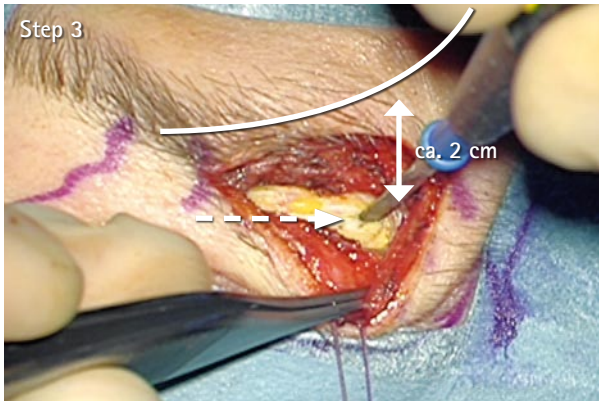

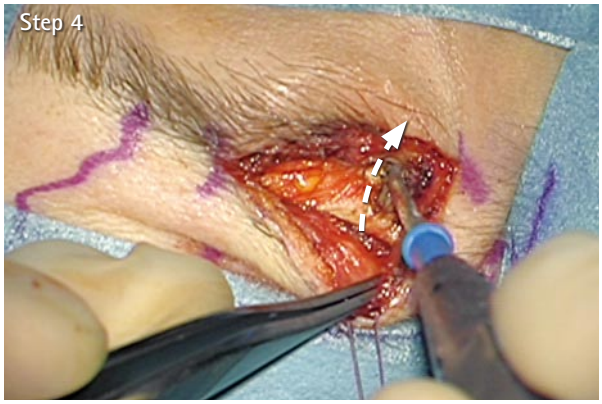

Figs. 30 – 33

Step 5. Using a sharp elevator, the bony surface is exposed. The temporalis muscle is dissected to lateral, the frontalis muscle strongly retracted in frontal direction (Fig. 34).

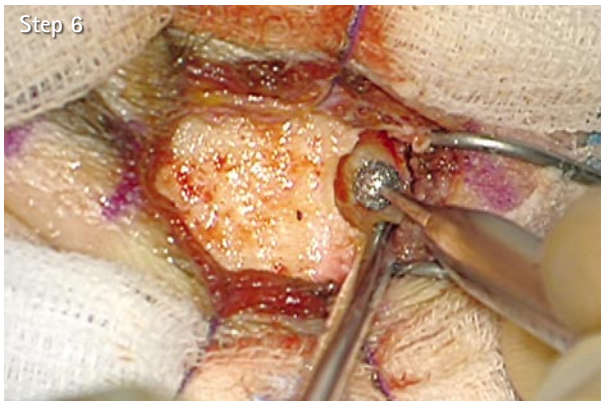

Step 6. The frontal and temporal muscles are retracted with sutures and hooks. After muscular dissection, a single fronto-basal burr hole should be made using a high-speed drill. For precise opening of the anterior fossa, the use of a cranial perforator cannot be recommended. Note that special attention must be given to this burr hole trephination, especially to its relationship to the frontal skull base and to the orbit. Optimal placement of the burr hole is lateral from the temporal line at the level of the frontal cranial base. In most cases, a delicate groove can be palpated with the finger indicating the level of the orbital roof (Fig. 35).

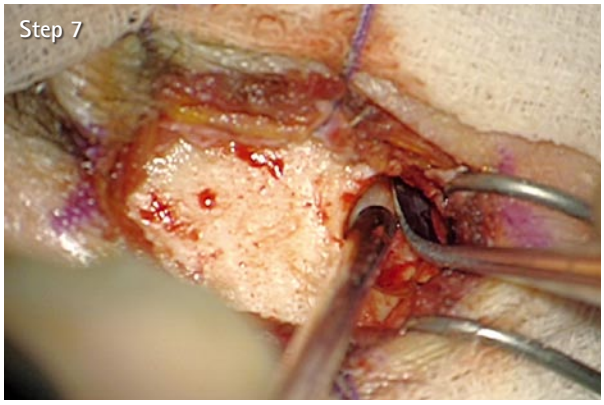

Step 7. The dural surface is exposed and carefully elevated with blunt dissector. The level of the frontal skull base can be exactly palpated. If used, correct placement of the burr hole can be controlled with the navigation device (Fig. 36).

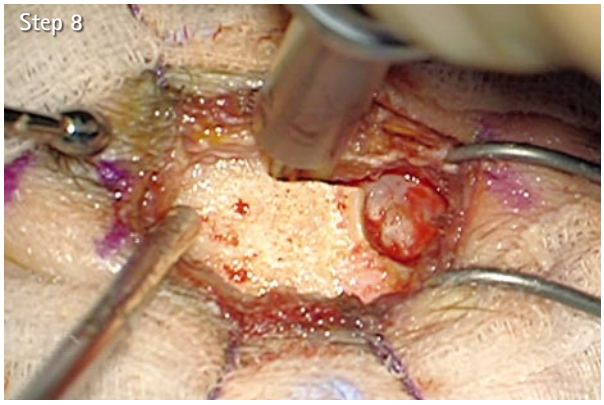

Step 8. After minimal enlargement of the hole with a small punch and mobilisation of the dura, a straight line should be cut with a high-speed craniotome parallel to the orbital rim in a lateral to medial direction, taking into account the lateral border of the frontal paranasal sinus (Fig. 37).

Figs. 34 – 37

Step. 9. Thereafter a "C" shaped line is created with the craniotome, cutting from the burr hole to the medial border of the previously performed frontobasal line (Fig. 38).

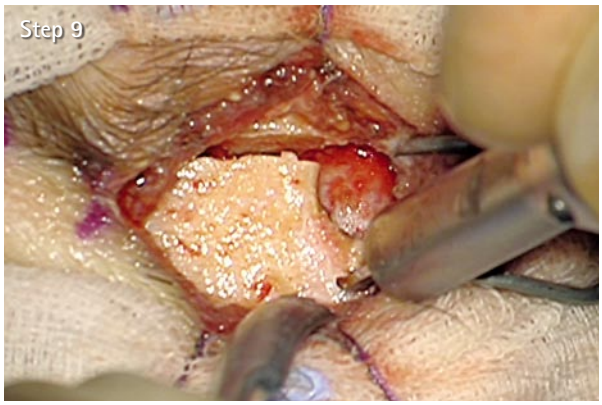

Step 10. Use of the craniotome is finished. Note the application of holding sutures and a Fisch-hook for optimal retraction of the frontal and temporal muscles (Fig. 39).

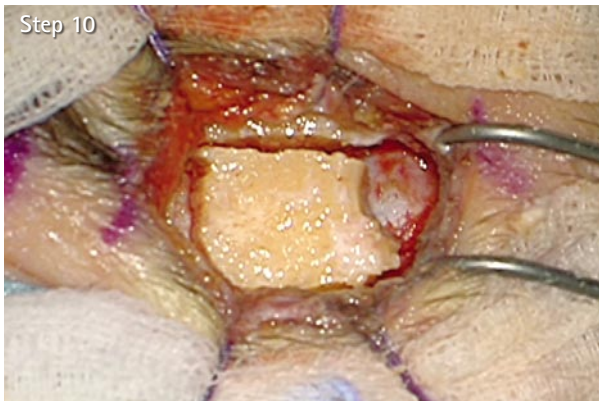

Step 11. A very important stage of the craniotomy after removal of the bone flap is high-speed drilling of the inner edge of the bone above the orbital rim under protection of the dura. Careful removal of this inner bone edge can significantly increase the angle for visualization and manipulation (Fig. 40).

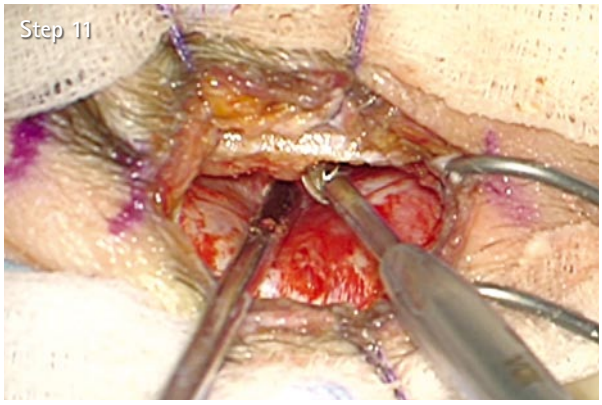

Step 12. The dura is then dissected from the orbital roof using a blunt dissector. If present, small osseous extensions, the juga cerebralia should also be drilled extradurally to obtain optimal intracranial visualization (Fig. 41).

Figs. 38 – 41

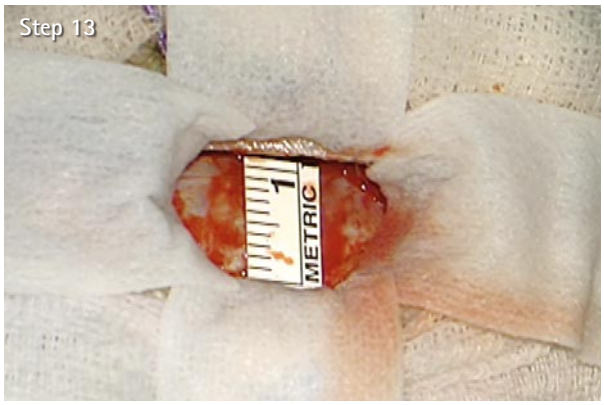

Step 13. Now, the supraorbital craniotomy is completed. Note limited, keyhole-sized approach, suitable for safe intracranial dissection. The skin is protected with wet patties (Fig. 42).

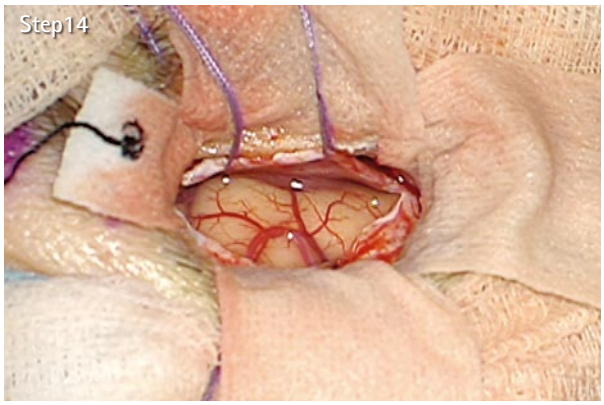

Step 14. The dura is opened in a simple "C" shaped form and retracted in basal direction. Note limited exploration of the cortical surface for minimally invasive intracranial dissection (Fig. 43).

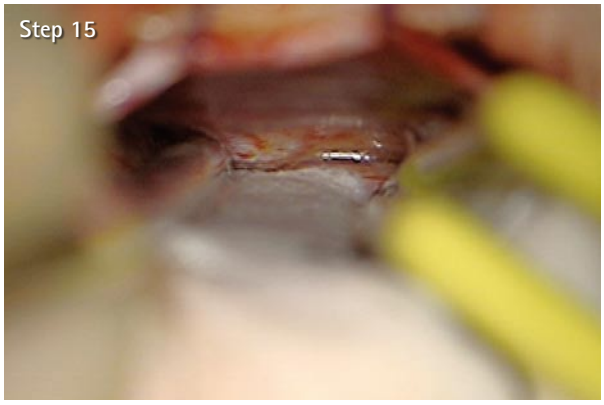

Step 15. The frontal lobe is carefully mobilized and the subfrontal pathway opened. By suitable positioning of the patient the frontal lobe sinks down, brain compression can be avoided according to the effective gravity related self-retraction. In this way, an elevator is not in use; the frontobasal brain surface is protected with sensitive patties (Fig. 44).

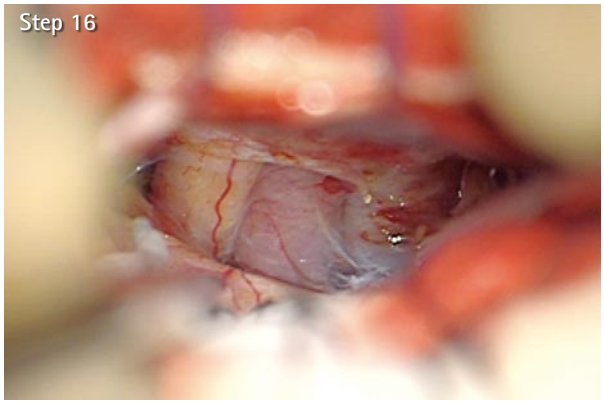

Step 16. Approaching the right optic nerve and carotid artery through the supraorbital keyhole without applying a brain spatula. Note sufficient observation despite the limited craniotomy size (Fig. 45).

Figs. 42 – 45

Illustrative case I

Incidental aneurysm of the middle cerebral artery
Approach: right supraorbital keyhole craniotomy

Case history

A 48-year-old female presented with an incidental aneurysm of the right MCA. The 5.3 mm large aneurysm was located at the origin of the early temporal branch, directed to lateral and inferior. The surface of the aneurysm was highly irregular with a small baby aneurysm at the dome (Fig. 46).

Treatment planning

Due to an appropriate risk of bleeding of the irregular configured aneurysm and patients panic anxiousness of subarachnoid hemorrhage, the indication for therapy was given. After interdisciplinary discussion concerning the treatment modality, the surgical solution was chosen; arguments favoring operation were the unfavorable dome neck aspect ratio and troublesome origination of the early temporal branch (Fig. 47).

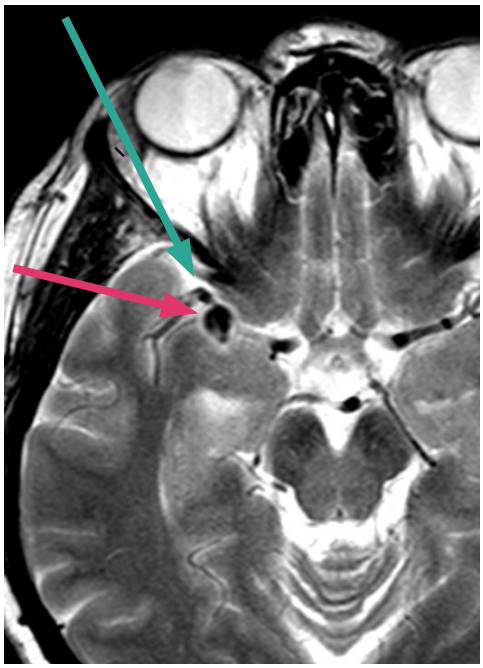

Fig. 46 *T2w axial MRI scan demonstrating incidental aneurysm of the right middle cerebral artery. Note the free subfrontal way to the aneurysm (green arrow); approaching from the lateral pterional direction, temporal manipulation is necessary for adequate observation of the Sylvian fissure (red arrow).*

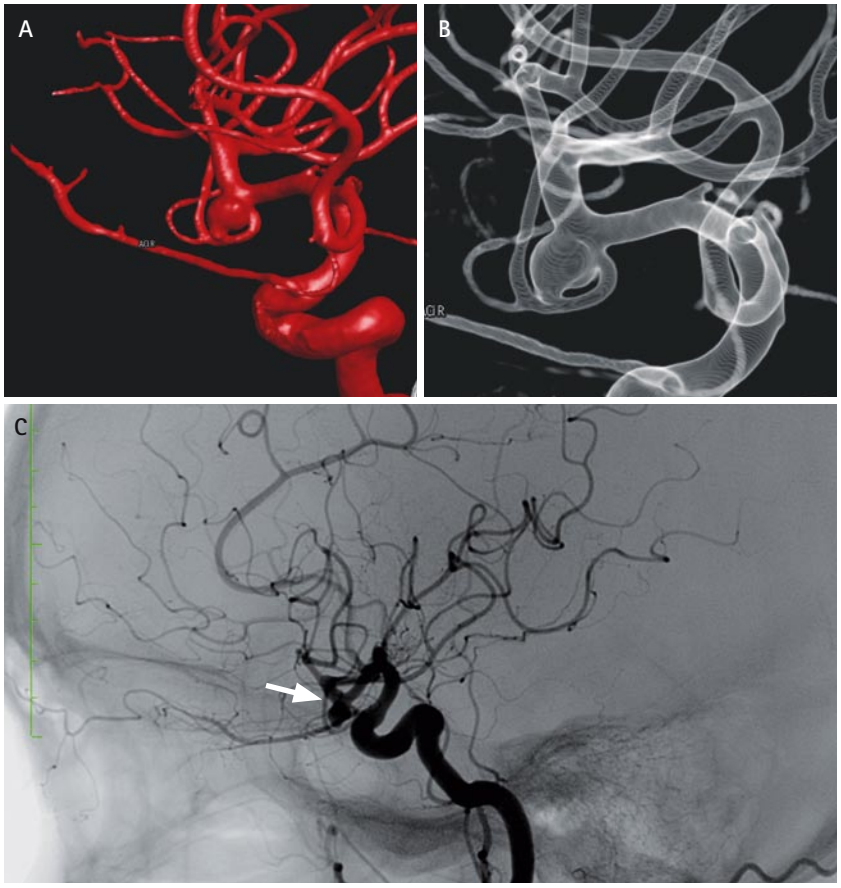

Fig. 47 *Digital three-dimensional rotational angiography (DSA) showing the irregular configured aneurysm of the MCA (A). Note unfavorable origination of the early temporal branch, incorporated into the neck region (B). Conventional DSA demonstrates the relation between the aneurysm and the bony skull base, requiring free subfrontal view to the neck region (C).*

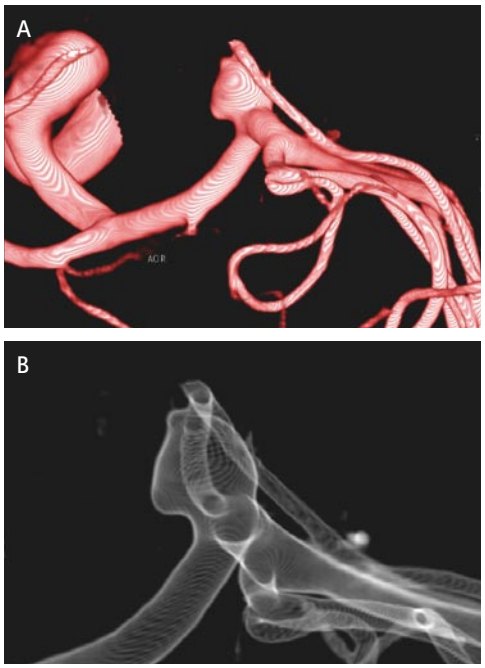

Fig. 48 *Angiographic view of the right MCA from the supraorbital direction. Through the subrontal way the MCA can be immediately approached without touching the temporal lobe; an early proximal control offers safe aneurysm dissection. In this case, origination of the temporal branch is hidden behind the dome: a clear indication of endoscopic TEAM technique with safe visualization in the shadow of the microscope light beam.*

Approach planning

The wide-neck aneurysm was directed to lateral and inferior at a sharp turn of the MCA main trunk; the origination of the early temporal branch was incorporated into the neck region. A standard pterional craniotomy would offer in this situation shortest approaching of the aneurysm. However, the trans-Sylvian route often causes laceration of eloquent veins and approach-related manipulation of the frontal and temporal lobe, which obscure the view to the MCA. In comparison, the supraorbital subfrontal approach provides an unhindered visualization of the MCA with early proximal control without dissection of the temporal lobe and injury of the Sylvian veins. In addition, the subfrontal view offers direct approaching of the neck region without touching the mostly lateral directed aneurysm dome (Fig. 48).

Positioning and preparation

The patient was placed supine on the operating table, the head was elevated, retroflexed and rotated to the left side. In this case 15° rotation was performed according to the Sylvian target area. During positioning, intraoperative SSEP/MEP neuromonitoring was prepared. Now, important anatomical landmarks of the osseous skull were palpated and the borders of the craniotomy were defined. The optimum skin incision followed the orbital rim. Navigation was used for controlling optimal surgical access (Fig. 49)

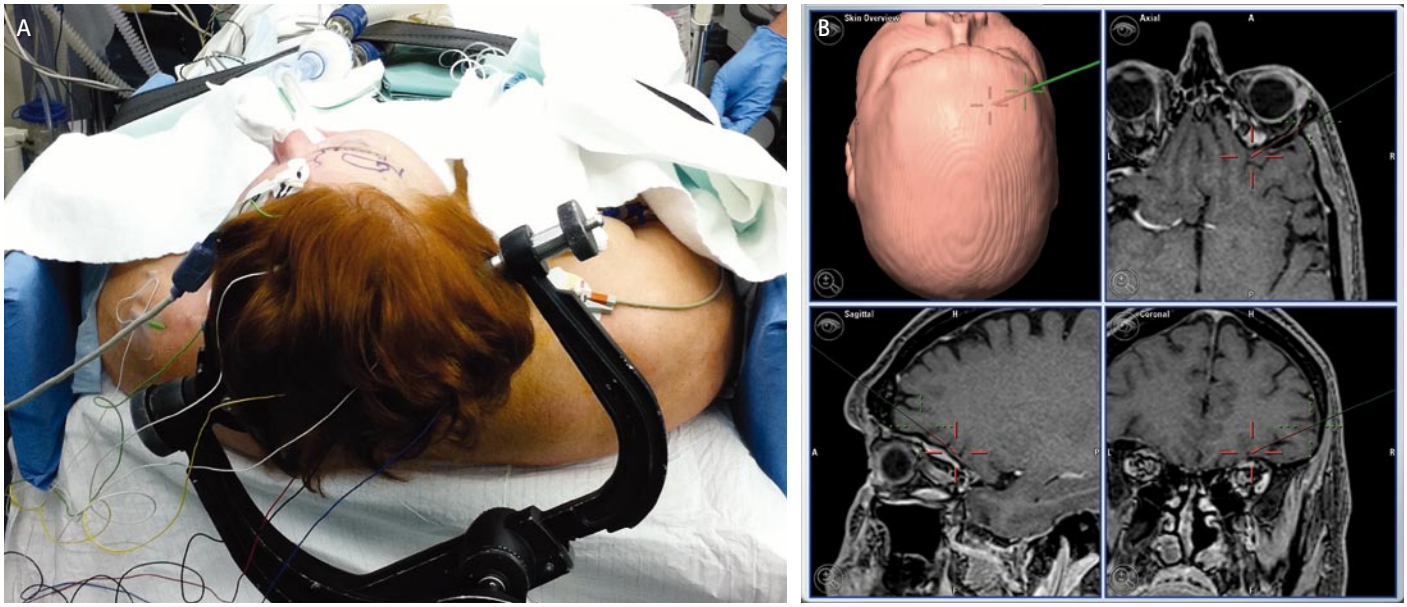

Fig. 49 *Patients positioning prepared for the right supraorbital craniotomy. Note approach planning with definition of the anatomical landmarks, craniotomy and the eyebrow skin incision (A). Using a navigation device, correct craniotomy placement and optimal surgical access was controlled (B).*

Surgery

Step 1. After creating a supraorbital keyhole and opening the dura mater in a curved fashion, the frontal lobe was carefully mobilised; sterile cotton pads were used for gentle dissection. The first step was sufficient drainage of CSF by opening the carotid and proximal Sylvian cisterns (Fig. 50).

Step 2. The Sylvian fissure was partially opened without manipulation on the temporal lobe; all Sylvian veins were preserved carefully, including a small branch crossing the aneurysm dome (arrow). The subfrontal approach offered optimal access to the main trunk of the MCA and to neck region without touching the dome of the aneurysm (Fig. 51).

Step 3. A 0° endoscope was now introduced into the surgical field with significantly increased light intensity and highly broadened observational field. Note the right Sylvian fissure and the MCA trunk without using cerebral retraction (Fig. 52).

Step 4. In a close-up position with the endoscope, anatomical details could be additionally recognised. Especially important was the relationship of the neck region to the origin of the early temporal branch, located behind the aneurysm (Fig. 53).

Step 5. The aneurysm was carefully dissected with a fine probe, allowing safe endoscopic visualization of the early temporal branch behind the aneurysm dome (Fig. 54).

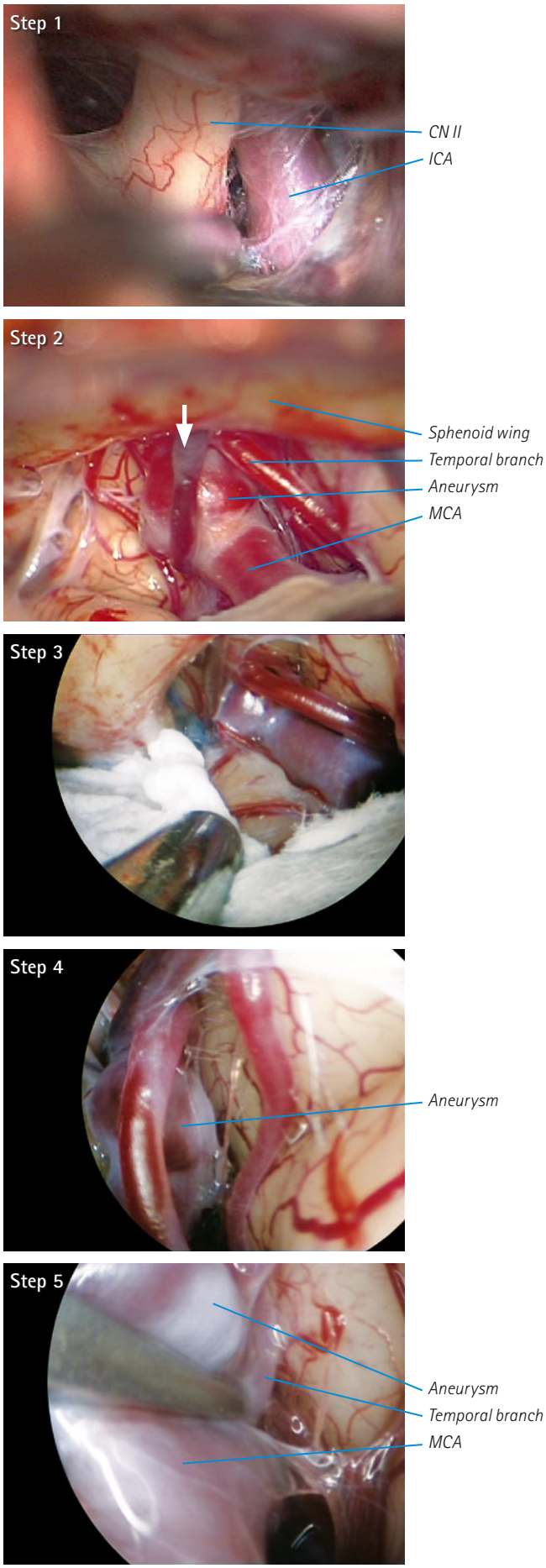

Figs. 50 – 54

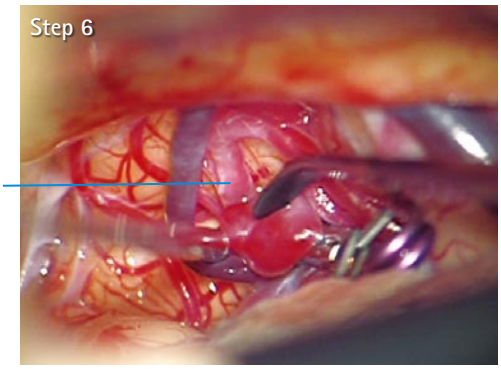

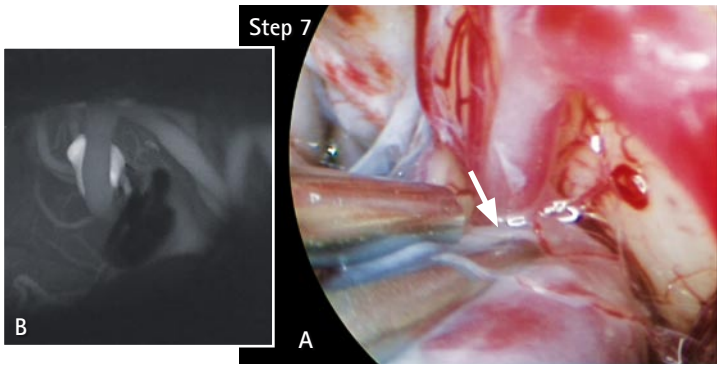

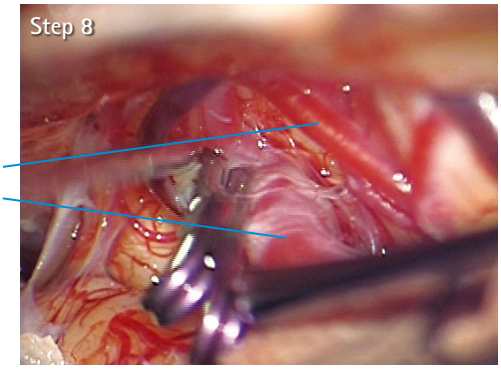

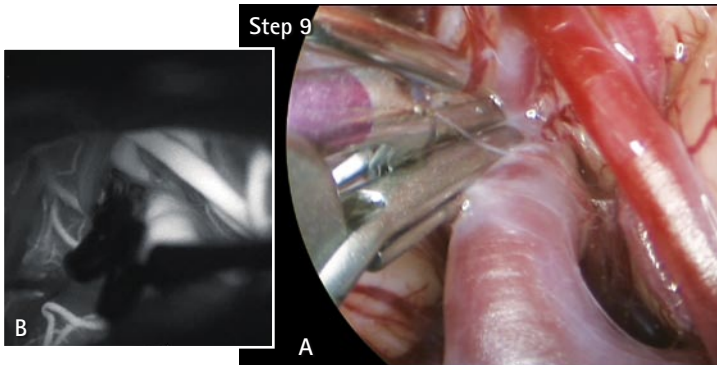

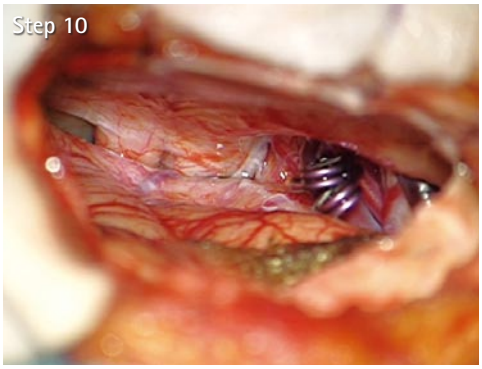

Figs. 55 – 59

Step 6. When the patho-anatomy of the aneurysm had been ascertained with the TEAM technique, the temporal branch was dissected from the aneurysm dome. This maneuver was technically difficult because of strong adhesions to the thin-walled aneurysm. Now, a straight aneurysm clip was positioned carefully without temporary occlusion of the MCA main trunk. For clip application through the narrow surgical corridor, a special tube-shaft instrument was used (Fig. 55).

Step 7. The endoscope was again used for checking clip placement. It was essential to obtain complete aneurysm closure and visualise the early temporal branch (A). Here, we could see well-perfused vessels, however, residual neck was suspected according to incorrect clip position (arrow). Now, ICG-angiography was used, thus verifying residual perfusion of the aneurysm (B). Note the preserved small temporal vein, crossing the aneurysm (Fig. 56).

Step 8. According to this finding, clip position was revised and a second clip was placed for additional safety in closure. During and after clipping process, no changes in SSEP/MEP monitoring could be detected (Fig. 57).

Step 9. Now, the endoscope was used again, verifying correct clip position with complete aneurysm closure (A). Doppler sonography and ICG angiography (B) showed normal flow in the MCA main trunk and in the temporal branch (Fig. 58).

Step 10. Photograph illustrates the limited 1cm dural opening with the aneurysm clips in the background. At the end of the intracranial procedure, the subarachnoid space was filled with artificial CSF at body temperature. The dural incision was closed watertight with continuous sutures. An important remark: during surgery no cerebral retractor was in site, only sterile cotton pads were used for gentle dissection (Fig. 59).

Postoperative course

The postoperative course was uneventful and the patient recovered rapidly without neurological symptoms. A postoperative angiogram showed complete closure of the aneurysm, the MRI scan no approach-related complications and no diffusion abnormalities (Figs. 60, 61). An optimal cosmetic result was achieved using the non-traumatic eyebrow skin incision (Fig. 62).

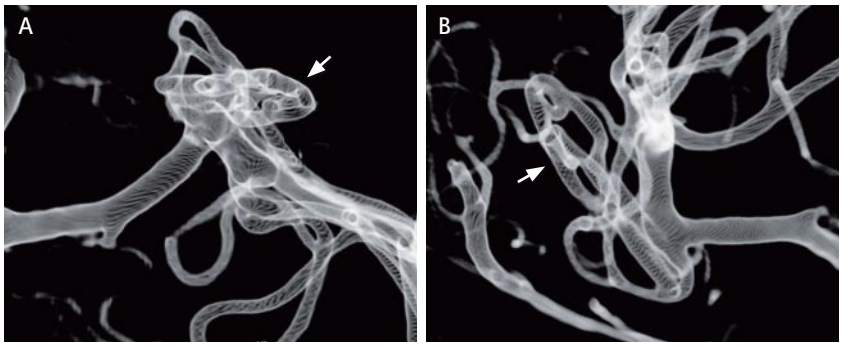

Fig. 60 *Postoperative rotational DSA showing complete closure of the aneurysm with reconstruction of the MCA main trunk and normal perfusion of the early temporal branch. Note both aneurysm clips (arrow).*

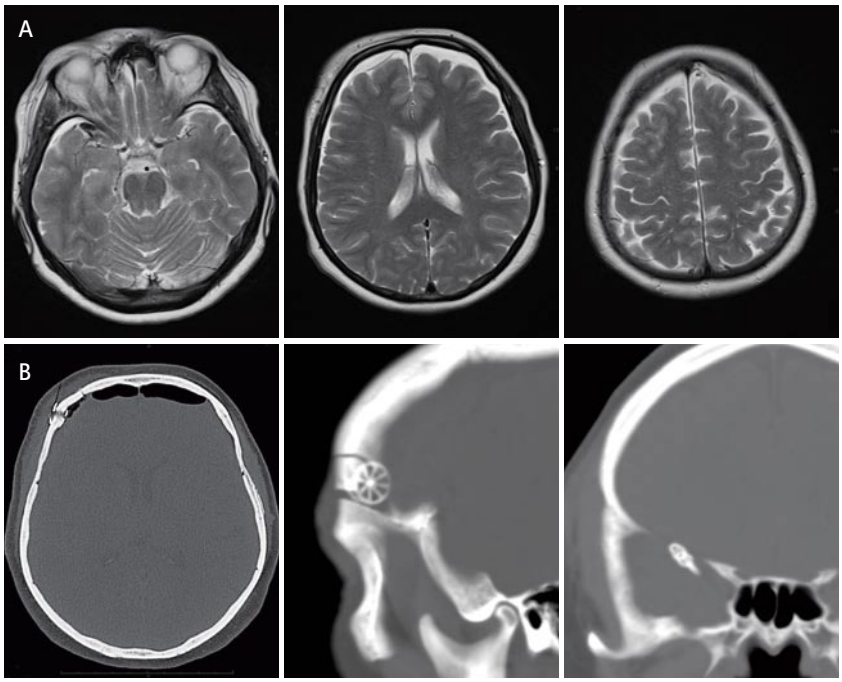

Fig. 61 *T2w postoperative MRI scan in axial plane, revealing no approach related complication (A). Minimal subdural effusion showed spontaneous remission. The triplanar CT scans with bone window demonstrate impressively the extension of the supraorbital approach in comparison to the clips (B).*

Fig. 62 *Patients appearance ten days after surgery with pleasant cosmetic outcome and uneventful complete recovery. Published with patients permission.*

The retrosigmoidal keyhole approach

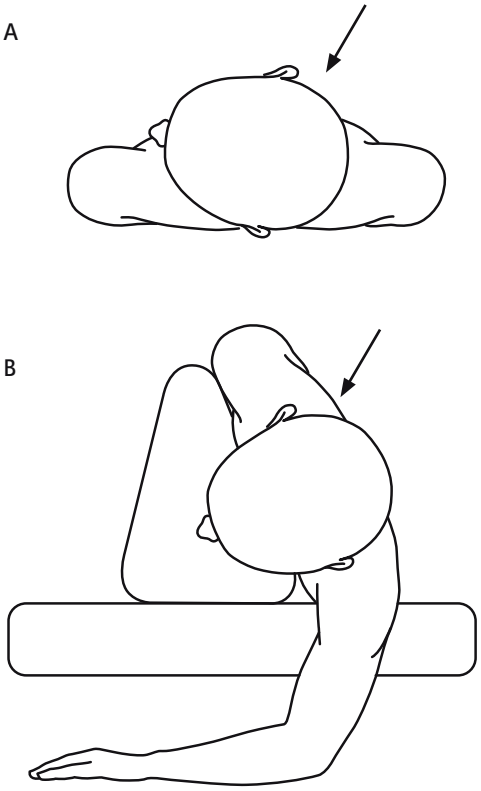

Fig. 63 *Patients positioning for retrosigmodal keyhole approach, using the supine (A) and park bench (B) techniques.*

Patient preparation

Patient positioning for operations in the cerebellopontine angle and foramen magnum is controversial; in our departments we advocate supine or park bench positioning (Fig. 63). The simple supine position can be recommended for slim patients with long necks and small shoulders. If, however, the patient is somewhat corpulent with a short neck and broad shoulders, we recommend the park bench position. Note the basic principle: the shoulder should not disturb later intracranial dissection! Irrespective of placement of the body, the head should be positioned with a rotation of 80-100°. Care should be taken not to compress the ventilation tube and the larynx and to facilitate venous drainage of the posterior fossa.

For anatomical orientation, important landmarks of the lateral temporo-occipital osseous skull such as the zygomatic arch, external auditory meatus, suprameatal crest, mastoid process and incisura, asterion and the external occipital protuberance are precisely defined. Special attention should be given to the course of the transverse and sigmoid sinuses. Usually, the transverse sinus runs from the external occipital protuberance in a lateral direction. "Riding on the asterion", the sinus passes the parietomastoid suture and follow the mastoid process.

After the essential orientation, the borders of the craniotomy are marked with a sterile pen. Usually, the occipitomastoid suture corresponds to the centre of the planned craniotomy (Fig. 64) Now, correct planning is controlled with the navigation device and optimal skin incision is defined.

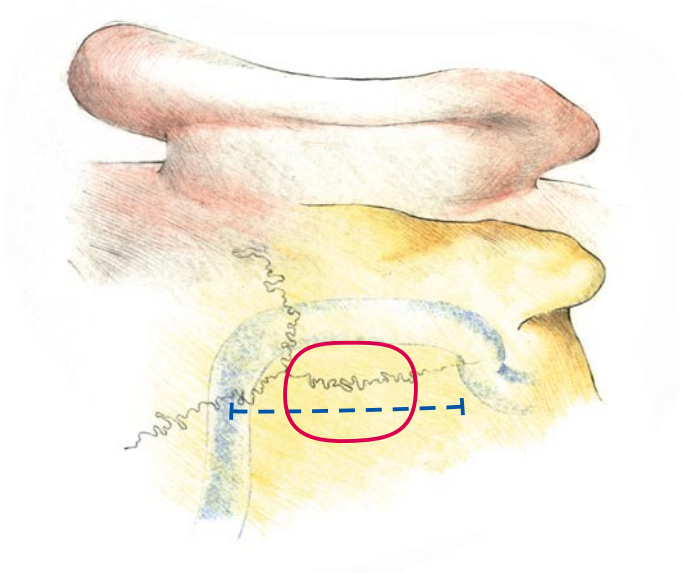

Fig. 64 *Photograph (A) and schematic (B) illustration demonstrating important anatomical landmarks of the lateral suboccipital region. After identification of these landmarks, borders of the craniotomy are marked and exact skin incision precisely defined. To avoid a big surprise we routinely use neuronavigation, thus controlling exact course of the transversal and sigmoid sinus.*

Surgical technique

Step 1. The hair is partially shaved in the retro-auricular area. A ca. 5 cm straight or slightly curved skin incision is made exposing the insertion of the sternocleidomastoid muscle. After bilateral retraction of the skin and the subcutaneous tissue, the retro-mastoidal periosteum and the sternocleidomastoid fascia are incised in a longitudinal straight fashion with a monopolar knife (Fig. 65).

Step 2. After retraction of the muscle, a tiny groove is usually visible on the bony surface according to the asterion. The asterion is usually located at the inferior margin of the transverse sinus just posterior to the transition into the sigmoid sinus. If possible, the parietomastoid, squamosal, lambdoid and occipitomastoid sutures are demonstrated exactly defining the course of the sinusoid vessels. Navigation is used for precise control (Fig. 66).

Step 3. After identification of the bony landmarks, a mid-sized trephine is used for a single burr-hole just inferiorly to the sigmoid sinus (Fig. 67).

Step 4. Thereafter, the free edge of the transverse and sigmoid sinus is exposed using a high-speed drill ensuring no damage to the sinuses. The dura is mobilized with blunt dissector (Fig. 68).

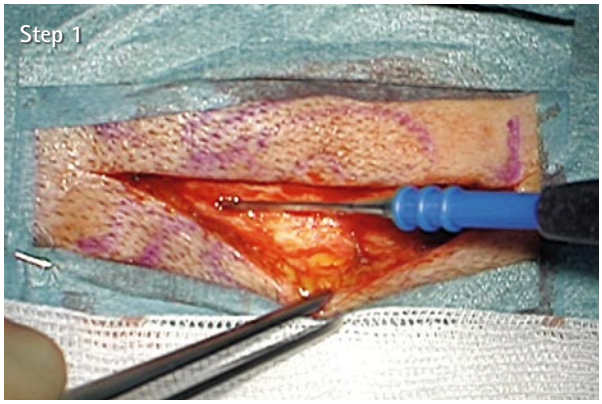

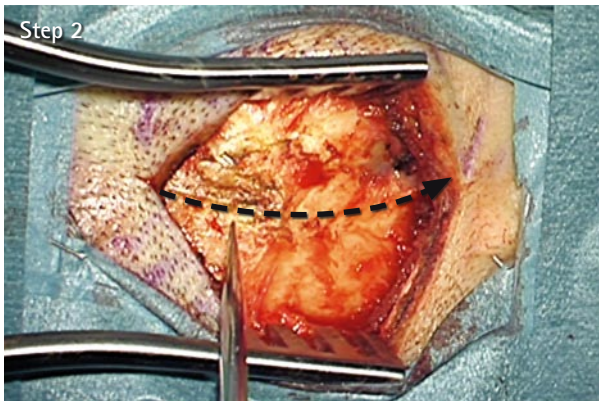

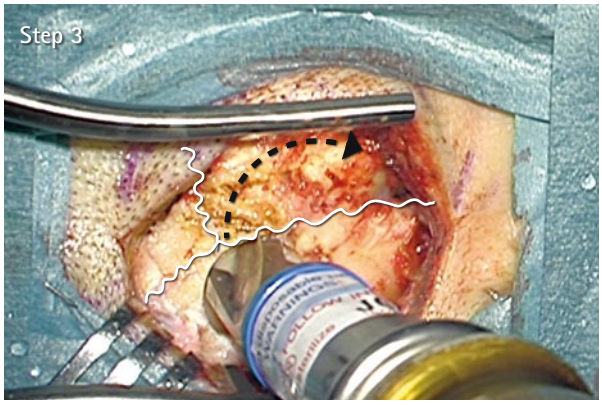

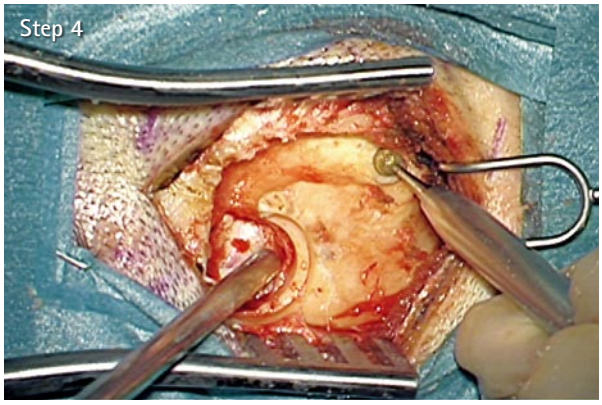

Figs. 65 – 68

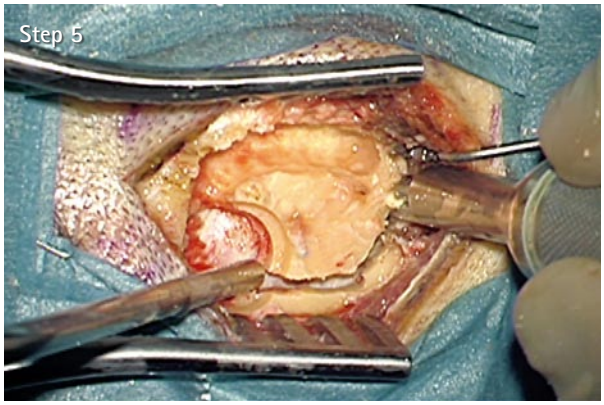

Step 5. The craniotomy should be created in an osteoplasic way, using a high-speed craniotome. From the previously performed burr hole, the suboccipital bone is cut in a curved line, thus creating a small keyhole (Fig. 69).

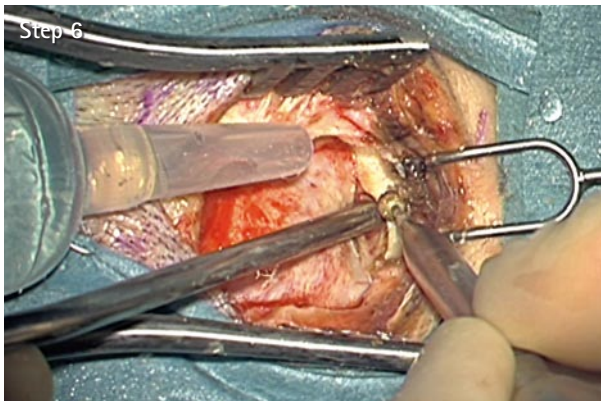

Step 6. The bone flap is then elevated carefully, avoiding laceration of the sinusoid vessels. An essential step of the approach is the removal of the inner edge of the craniotomy using a diamond drill and fine punches whilst protecting the dura. With careful removal of this inner bone edge, the angle for visualization and manipulation can be significantly increased. It is especially important to drill away the basal occipital bone: the free basal suboccipital view is necessary for early opening of the cisterns. (Fig. 70).

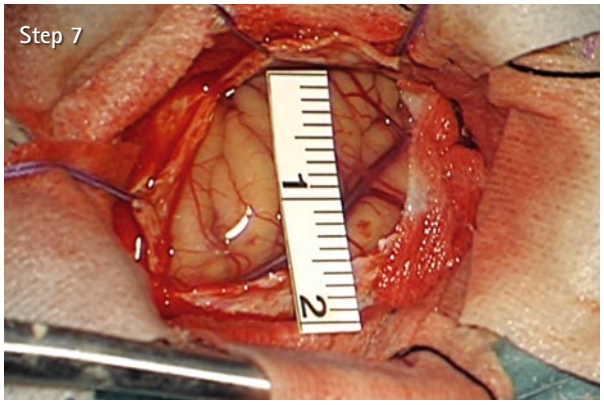

Step 7. The dura is opened in curved fashion. Note limited exploration of the cerebellar surface (Fig. 71).

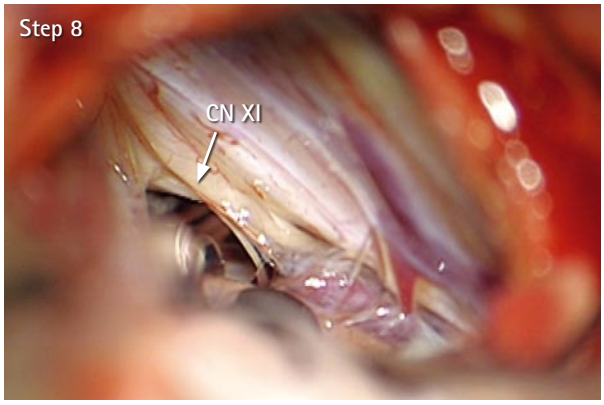

Step 8. The cerebellar surface is carefully mobilized with sensitive patties. According to the adequate supine or park bench positioning, no cerebellar retraction is necessary for reaching the subarachnoidal spaces; after opening of arachnoid membranes and removal of CSF the cerebellum sinks spontaneously down with unhindered exploration of the cerebellopontine angle (Fig. 72).

Figs. 69 – 72

Illustrative Case II

Meningioma of the lower clivus and foramen magnum Approach: retrosigmoidal lateral suboccipital keyhole craniotomy

Case history

A 44-year-old female presented with slight gait disturbances and severe neck pain. Neurological investigation showed mild ataxia of the extremities and left sided hypoglossal palsy with tongue atrophy; therefore MRI of the brain was performed.

Treatment planning

The MRI scan showed a large meningioma of the lower clivus and ventral foramen magnum with severe displacement of the ponto-medullar brain stem according to a magnificent space occupying effect (Fig. 73). The highy vasularized tumor showed homogeneous contrast enhancement. As first step of treatment, DSA was performed, showing supplying vessels from both ascending pharyngeal and left vertebral arteries. Interventional embolization was performed successfully under local anesthesia; the MRI scan 5 days after treatment showed markedly de-vascularization and central tumor necrosis.

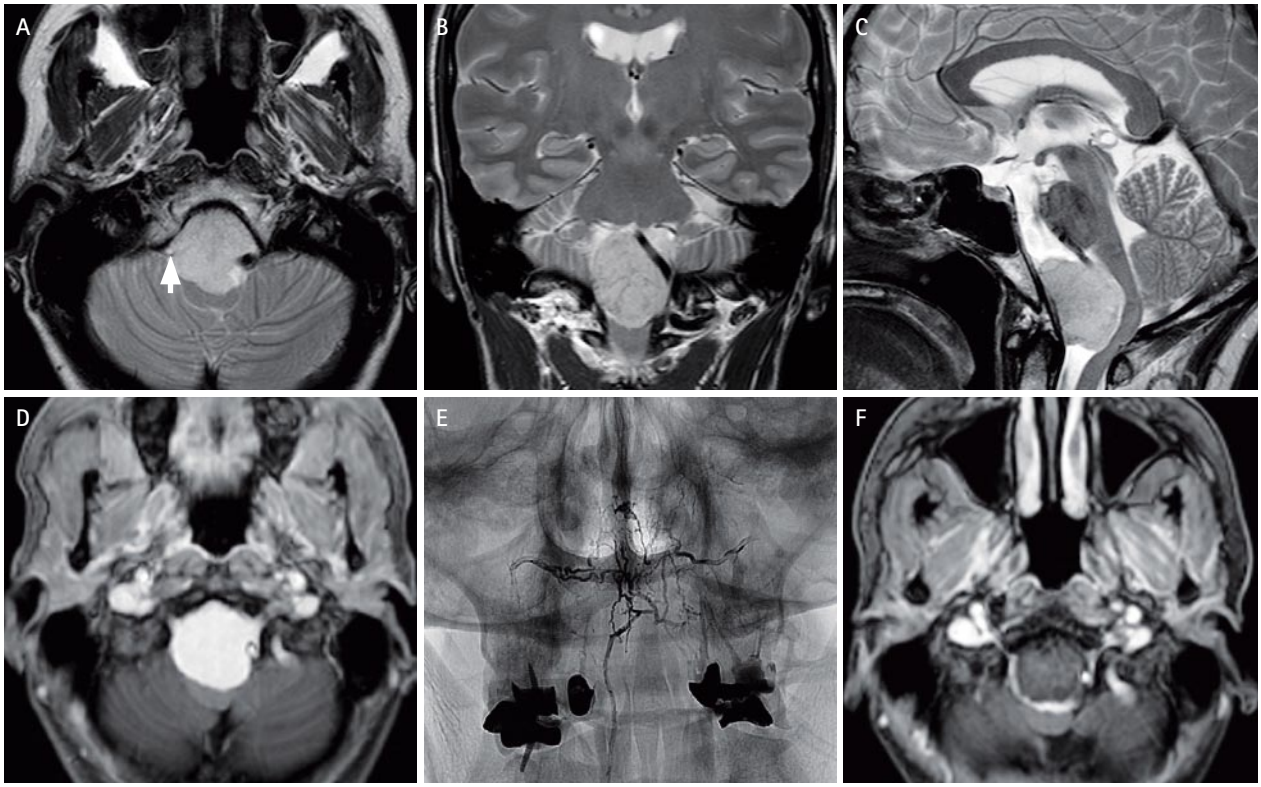

Fig. 73 *T2w MR imaging in axial (A), coronar (B) and sagittal (C) view demonstrating large meningioma of the caudal clivus and foramen magnum. Note hypoplasitc right vertebral artery (arrow) and severe herniation of the medulla. T1w contrast assisted axial scan shows marked enhancement (D), in the subsequently performed DSA the main tumor supplying vessels could be successfully occluded (E). Note the tumor vessels after transarterial Onyx® embolization. Five days after interventional treatment, contrast assisted T1w axial MR scan reveals marked de-vascularization (F).*

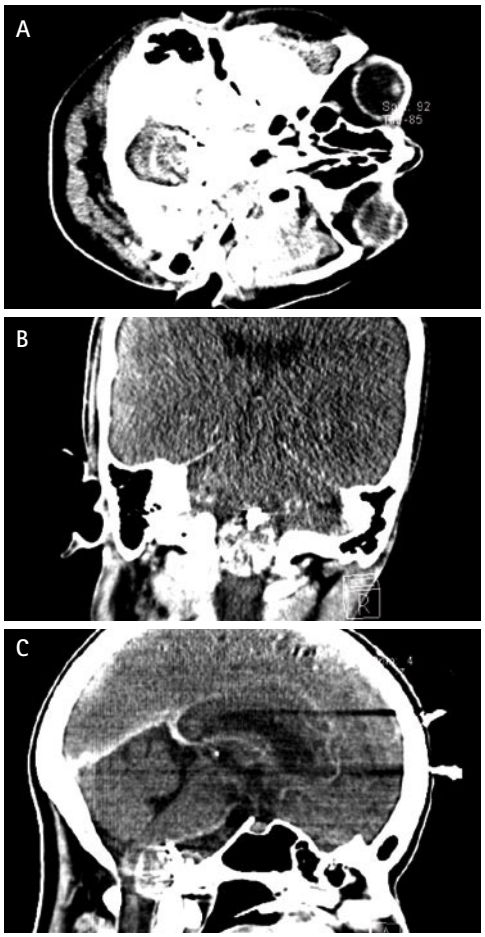

Fig. 74 *iCT demonstrating tumor extension in the foramen magnum.*

On account of the severe space occupying effect, indication for surgical removal was given. For safe surgery intraoperative neuromonitoring was prepared, analysing SSEP/MEP, and all caudal nerves.

Approach planning

Ventral located foramen magnum meningiomas are usually exposed via the far lateral craniotomy. However, the transcondylar approach often causes significant approach-related traumatization of the craniocervical junction. In comparison, the retrosigmoidal keyhole craniotomy offers minimally invasive exploration; using the TEAM technique, hidden parts of the field can be visualized, overcoming the limitation of the small-sized cranial opening. In this illustrative case, we have used a right-sided approach according to a hypoplastic right vertebral artery.

Positioning and preparation

Patients positioning was carefully performed under continuous SSEP monitoring. To avoid significant head rotation by the giant foramen magnum tumor, park bench position was performed (Fig. 75). Care was taken not to compress the ventilation tube and the larynx and to avoid venous congestion within the posterior fossa. Now, intraoperative CT was performed with registration of the integrated navigation system (Fig. 74, 75B)

The hair was minimally shaved in the retro-auricular area. For preoperative orientation, important anatomical landmarks of the lateral temporo-occipital osseous skull were defined and the borders of the craniotomy were marked; correct placement of the proper skin incision was controlled with the navigation device.

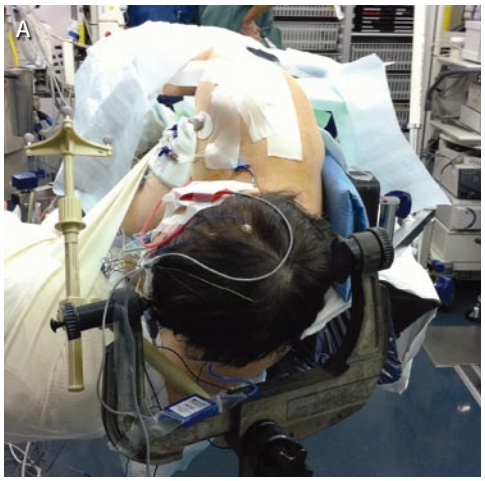

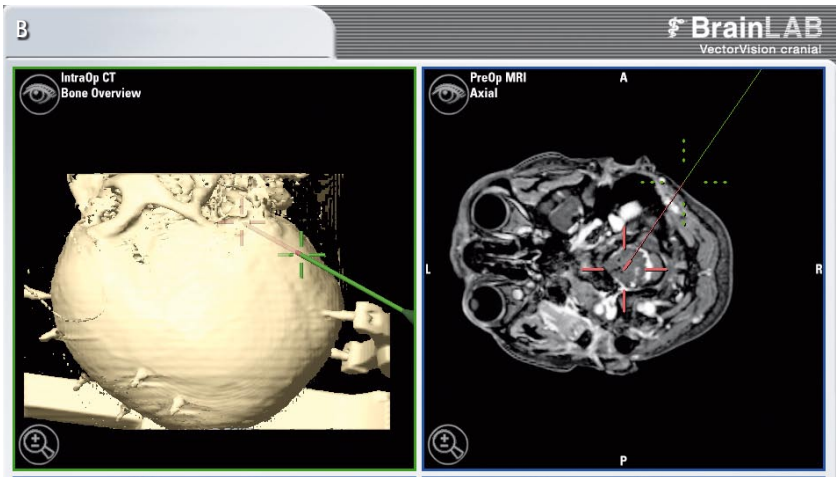

Fig. 75 *To avoid significant head rotation, park bench positioning was used under continuous SSEP monitoring (A). After determination of anatomical landmarks and approach planning, correct placement of the craniotomy was controlled with the navigation device (B).*

Surgery

Step 1. As the first step of the intradural dissection, the cerebellum was gently mobilized with cotton pads and the lateral cerebello-medullar cistern was approached. Along the accessory nerve, arachnoid membranes were opened with a diamond knife and CSF was removed for effective decompression of the posterior fossa. Note the CN X and CN XII after opening these arachnoid layers; in the background, the tumor appears. Due to the optimal positioning and CSF removal, the cerebellar hemisphere deflated and the surgical pathway opened spontaneously without any retraction (Fig. 76).

Step 2. As a next step, a 0° endoscope was introduced for primary anatomical orientation with clear visualization of the pathoanatomical structures in the overview (Fig. 77).

Step 3. In a close-up position, bundles of the CN IX, X and XI and the hypoplastic right vertebral artery can be observed; note the CN XII, severely displaced by the tumor mass (Fig. 78).

Step 4. Anterior from the CN IX, the prepontine region is entered, visualizing the CN V, VI and VII; in the background, the BA appears (Fig. 79).

Step 5. Caudal from the inferior tumor pole, the surface of the brain stem becomes visible within the foramen magnum; note the first dorsal cervical roots (Fig. 80).

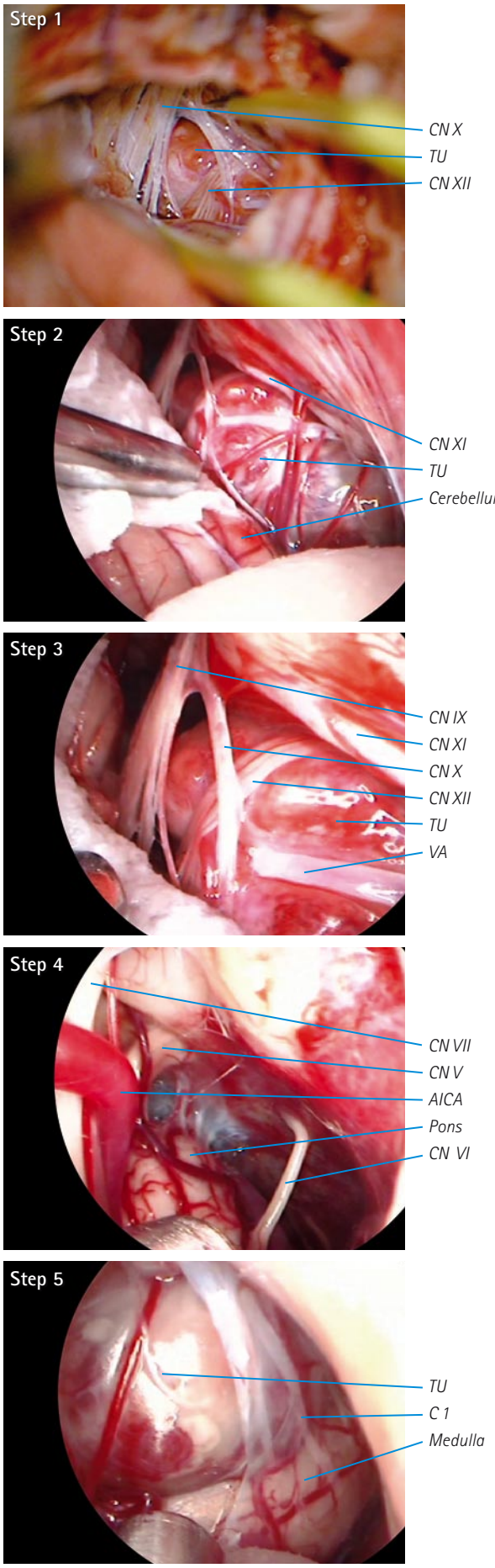

Figs. 76 – 80

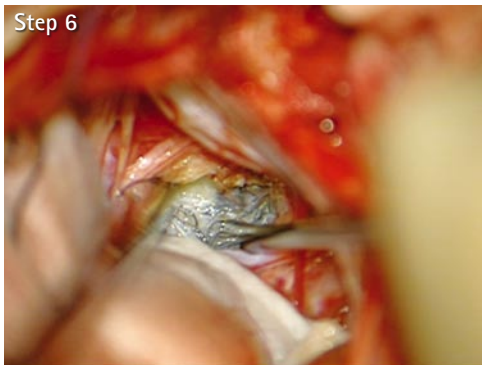

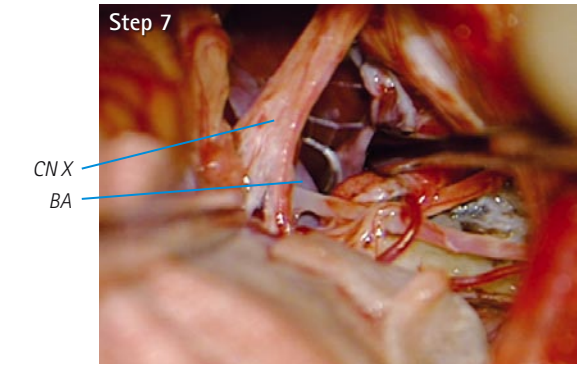

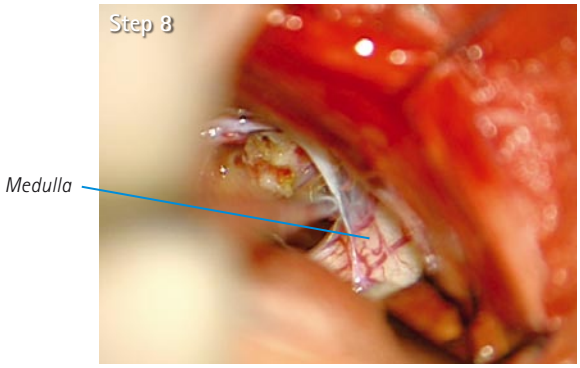

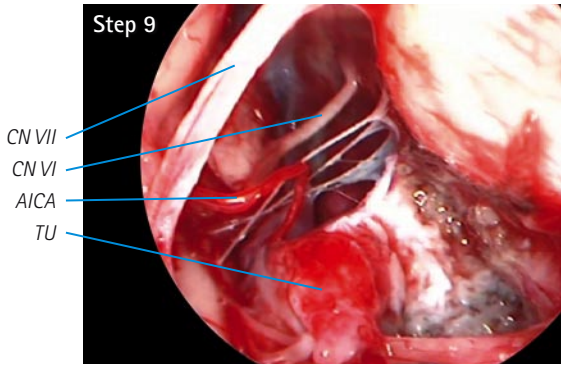

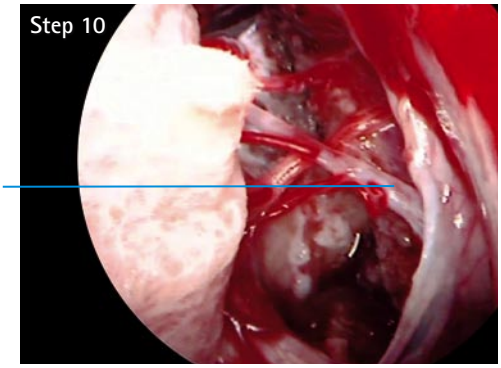

Figs. 81 – 85

Step 6. Again with microscopic visualization, the capsule of the meningioma was opened and an effective debulking was achieved using an ultrasonic aspirator and tube-shaft grasping instruments. Note the marked devascularization after effective embolization, making resection easier and faster. The silvery substance corresponds to the Onyx® material (Fig. 81).

Step 7. After decreasing in size, the tumor was carefully freed from the surroundings. At first, the cranial tumor pole was mobilized from the vertebrobasilar junction and from the vagal nerve (Fig. 82).

Step 8. Thereafter, the caudal tumor pole was detached from the brainstem (Fig. 83).

Step 9. After partial tumor resection, the endoscope was used again according to a real TEAM technique. Note the cranial resection-field with the facial and abducent nerves (Fig. 84).

Step 10. Looking in caudal direction with the scope, the hypoplastic right vertebral artery with important medullar perforators can be seen again. Note protection of the cerebellum with patties, without using a brain spatula (Fig. 85).

Step 11. Again with microsurgical technique, the tumor was completely removed. Note direct stimulation of the accessory nerve (Fig. 86).

Step 12. The endoscope was changed now to a 30° optic for proper visualization of the foramen magnum. Note complete resection in the cranial field of resection (Fig. 87).

Step 13. Retracting the endoscope in the caudal direction, the foramen magnum can be observed. Note the opposite left vertebral artery and the fully decompressed brain stem. With the endoscopic visualization no residual tumor could be detected. For securing complete resection iCT was performed, thus excluding remnants of the meningioma (Fig. 88).

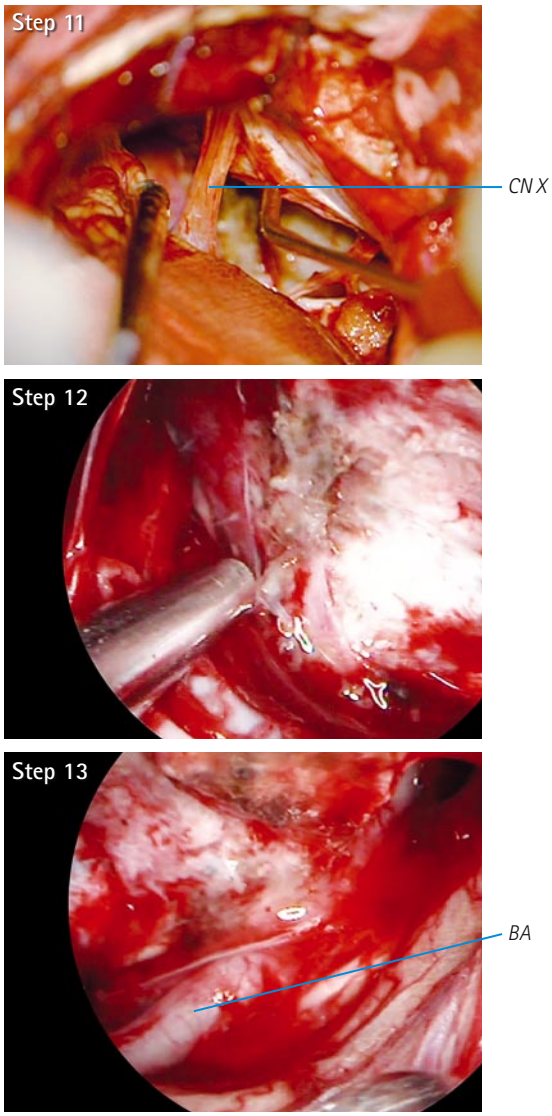

Figs. 86 – 88

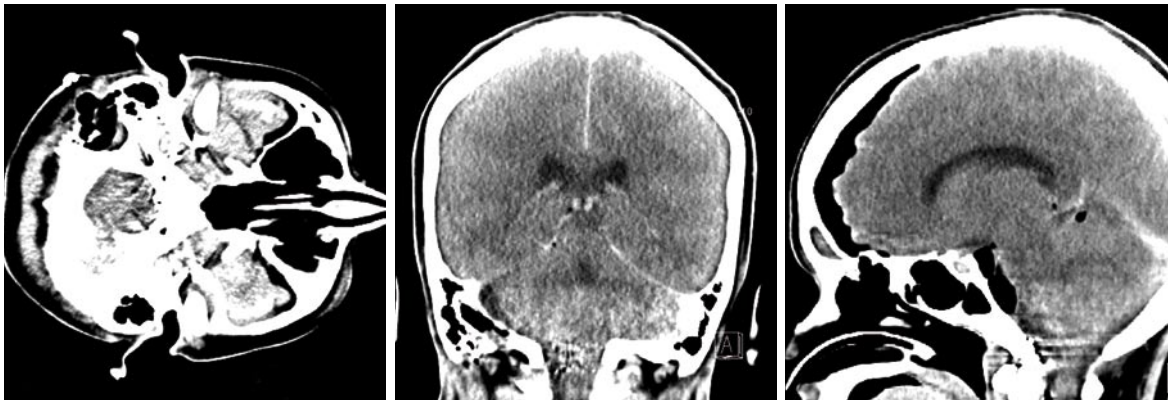

Fig. 89 *iCT performed in park bench position, showing no surgical complication and proper tumor resection.*

Postoperative course

The early postoperative course was uneventful. An initial investigation showed marginal dysphagia and huskiness, but no cerebellar or brainstem symptoms. MRI on the first postoperative day showed no tumor remnants. 6 days after surgery wound revision was necessary, on account of CSF leakage and rhinoliquorrhea; however, the later course was without any complications.

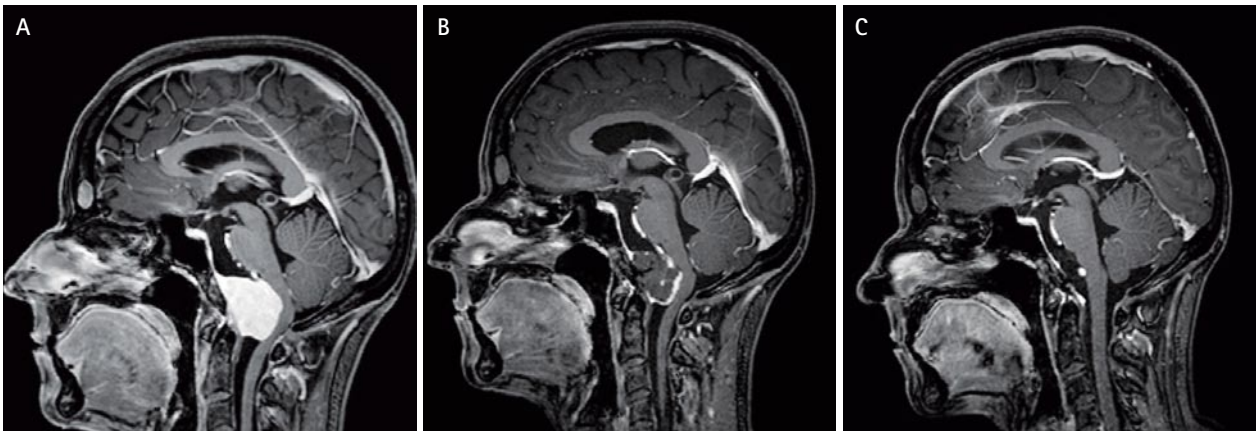

Fig. 90 *T1w MRI scans with contrast medium in sagittal view showing the status before treatment (A), after embolization (B) and after complete surgical resection (C).*

Fig. 91 *Patients condition at discharge 7 days after tumor resection. Note stable standing without cerebellar, brainstem, or cranial nerve symptoms (A). The hypoglossal palsy with muscular atrophy (B) showed 3 months the later marked improvement (C). Published with patients permission.*

Abbreviations

ACA	anterior cerebral artery
BA	basilar artery
C 1	first dorsal cervical root
CN II	optic nerve
CN III	oculomotor nerve
CN IV	trochlear nerve
CN V	trigeminal nerve
CN VI	abducent nerve
CN VII	facial nerve
CN X	vagal nerve
CN XI	accesory nerve
CS	cavernous sinus
ICA	internal carotid artery
PCA	posterior cerebral artey
PICA	posterior inferior cerebellar artery
TU	tumor
VA	vertebral artery