ELSEVIER

Technique

Surgical Technique of the Supraorbital Key-Hole Craniotomy

Robert Reisch, M.D., Axel Perneczky, M.D., Ph.D., and Ronald Filippi, M.D.
Department of Neurosurgery, Johannes-Gutenberg University, Mainz, Germany

Reisch R, Perneczky A, Filippi R. Surgical technique of the supraorbital key-hole craniotomy. Surg Neurol 2003;59:223–7.

BACKGROUND
The enormous development of microsurgical techniques and instrumentation together with preoperative planning using the excellent preoperative diagnostic facilities available, enables neurosurgeons to treat more complicated diseases through smaller and more specific approaches.

METHODS
The technical details of the supraorbital key-hole craniotomy are described in this article as it has been evolving in our experience for more than 10 years. After an eyebrow skin incision with careful soft tissue dissection and single frontobasal burr-hole trephination, a supraorbital craniotomy is carried out with a diameter of about 1.5 × 2.5 cm. As a real frontolateral approach, the supraorbital craniotomy avoids removal of the orbital rim, the lesser sphenoid wing or the zygomatic arch.

RESULTS AND CONCLUSIONS
The supraorbital craniotomy allows wide intracranial exposure of the deep-seated supra- and parasellar region, according to the concept of key-hole approaches. The limited craniotomy requires minimal brain retraction thus significantly decreasing approach-related morbidity. In addition, the short skin incision within the eyebrow, the careful soft tissue dissection, and the single burr hole trephination result in a pleasing cosmetic outcome.

KEY WORDS
Minimally invasive neurosurgery, supraorbital craniotomy, surgical approach, surgical anatomy.

The first supraorbital, subfrontal approach for resection of a skull base meningioma was reported by Fedor Krause in the first volume of his pioneering work *Experiences in Surgery of the Brain and Spine*, published in 1908 [11]. Since then, various authors have been describing different modifications to enhance the exposure offered by the subfrontal route [2,4–7,10,12,14–16,17,18]. However, in his pioneering description, Krause had already realized the essence of the subfrontal supraorbital exposure: the suprasellar anatomic structures are free for surgical dissection from an anterior direction of view and the anterior part of the temporal lobe does not obscure the access to deep-seated areas.

In our institution, we have been using the supraorbital subfrontal approach for more than 10 years. During a 5-year period between January 1997 and December 2001, there were 511 patients suffering from a variety of tumors and vascular lesions within the anterior, middle, and posterior cranial fossa. In this report, we will describe the basic surgical technique of our supraorbital key-hole craniotomy through an eyebrow skin incision.

Surgical Technique

Patient Positioning

The patient is placed supine on the operating table; the head is fixed in a three-pin Mayfield holder. The single pin of the head fixator should be placed in the opposite frontal area to allow free manipulation on the ipsilateral side during the procedure. Positioning of the head requires that the neck be extended with the head above the heart level to facilitate venous drainage during surgery. Thereafter, the head is rotated to the contralateral side, the degree of rotation dependent on the precise location of the lesion. According to the individual pathoanatomical structures, for ipsilateral temporomesial lesions a 15° rotation is sufficient; however, by choosing the correct angle between 30° and 60°, one can also make contralateral lesions visible. Note that right-handed surgeons performing a left-sided craniotomy need more rotation to allow an ergonomic working position. The maneuver of retroflexion supports gravity-related self-retraction of the frontal lobe, but is dependent on the precise anatomic and pathologic situation. Lesions in close proximity to

Address reprint requests to: Dr Robert Reisch, Neurochirurgische Klinik der Johannes-Gutenberg Universität Mainz, Langenbeckstr. 1., D-55131, Mainz, Germany.
Received July 19, 2002; accepted August 20, 2002.

360 Park Avenue South, New York, NY 10010–1710
0090-3019/03/$–see front matter
doi:10.1016/S0090-3019(02)01037-6

1 Artistic drawing presenting the most important anatomic landmarks of the frontotemporal area such as the structures of the osseous skull and the superficial neurovascular structures. Note the definition of the skin incision and the supraorbital key-hole craniotomy.

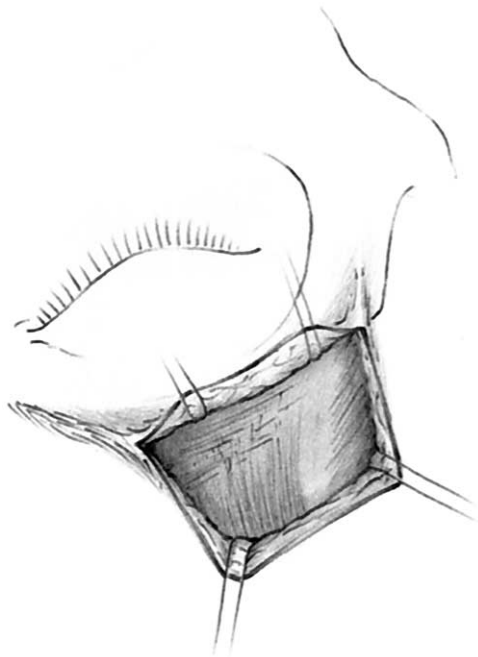

2 After eyebrow skin incision, the subcutaneous tissue is dissected upwards observing the frontolateral muscular layer. The skin flap is retracted temporarily with stitches achieving optimal exposure of the occipitofrontal, orbicular, and temporal muscles.

the frontal skull base, such as proximal aneurysms, require a retroflexion of 10–15°. Structures situated more cranially, such as lesions of the third ventricle, need more retroflexion. In addition, the head may be lateroflected about 10° to the contralateral side, allowing an ergonomic working position for the surgeon.

ANATOMIC ORIENTATION AND SKIN INCISION

For the appropriate eyebrow skin incision the important anatomic landmarks of the osseous skull such as the glabella, the frontal paranasal sinus, the supraorbital foramen, the temporal line, the frontobasis, the impression of the Sylvian fissure, and the zygomatic arch are precisely defined and marked with a sterile pen (Figure 1). Special attention should be given to the course of the superficial neurovascular structures, such as the supraorbital nerves and artery. Only then should the borders of the craniotomy be marked, taking into consideration the position of the lesion and the landmarks drawn on the skin. After defining the craniotomy, the individual optimum line of the skin incision is marked with the pen. Usually this skin incision is placed lateral to the supraorbital nerve running within the eyebrow and extends some millimeters beyond the lateral edge of the eyebrow. To achieve cosmetically acceptable results, the incision may follow the orbital rim and should not extend medial to the supraorbital nerve, thereby avoiding frontal numbness.

DISSECTION OF SOFT TISSUES

After skin incision, the skin flaps are temporarily retracted with four stitches, exposing the frontal belly of the occipitofrontal muscle and the orbicular and temporal muscles (Figure 2). The frontal muscles are incised with a monopolar electrode knife parallel to the glabella; the temporal muscle is stripped from its bony insertion (Figure 3). Using strong stitches, the temporal muscle is retracted laterally and the frontal muscle upwards. Note that the frontal and orbicular muscles should gently be pushed downwards to the orbit; careful dissection and minimal retraction of this muscular layer is essential to prevent postoperative periorbital hematoma.

CRANIOTOMY AND DURAL OPENING

Using a high-speed drill, a single frontobasal lateral burr hole is placed posterior to the temporal line. Special attention must be given to the placement of this burr hole with regard to its relationship to the frontal skull base and to the orbit. Note that correct placement of the burr hole, but incorrect direction of drilling may penetrate the orbit and not the anterior fossa. After minimal enlargement of the hole with fine punches and mobilization of the dura, a high-speed craniotome is used to saw a straight line parallel to the glabella in a lateral-to-medial direc-

Surg Neurol 225
2003;59:223–7

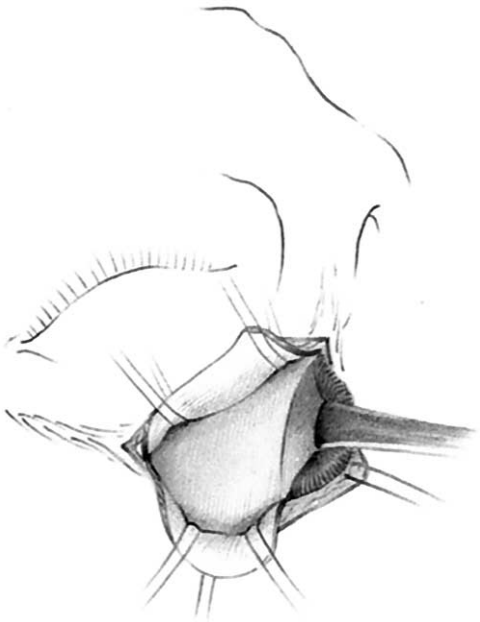

3 The temporal muscle is stripped from its bony insertion and retracted laterally, the frontal muscle is dissected from the orbicular muscle and retracted upwards with strong stitches. Note that the orbicular muscles should be gently pushed downwards to the orbit.

tion, taking into account the lateral border of the frontal paranasal sinus. Thereafter a C-shaped line is sawed from the burr hole to the medial border of the previous frontobasal line, thus creating a bone flap with a width of about 20–25 mm and a height of about 15–20 mm (Figure 4). An important step of the craniotomy after removal of the bone flap is the

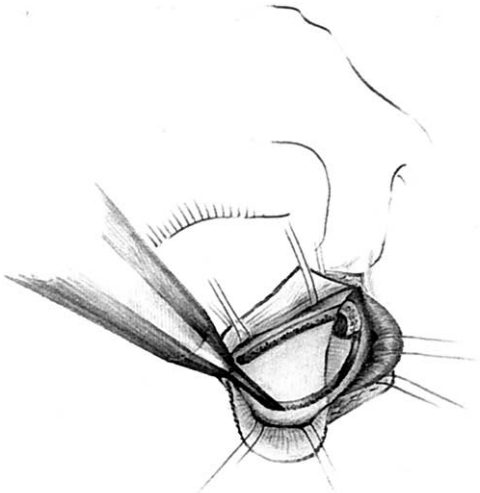

4 After burr hole trephination behind the temporal line, a straight line is cut with the craniotome from the burr hole in a medial direction, just parallel to the glabella. Thereafter the craniotomy is completed with a C-shaped sawing line.

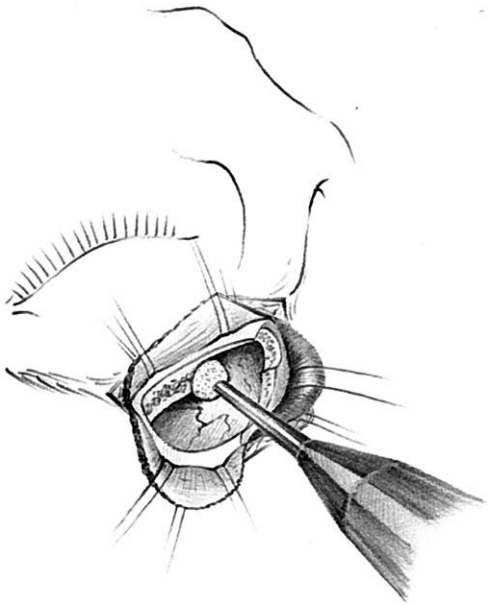

5 After removal of the bone flap, the inner edge of the bone should be removed above the orbital rim using a high-speed drill. After careful removal of this inner bone edge, the angle for intracranial visualization and manipulation can significantly be increased. After craniotomy is completed, an opening with a width of about 10–25 mm and a height of about 15–20 mm is created.

drilling of the inner edge of the bone above the orbital rim under protection of the dura using the high-speed drill (Figure 5). After careful removal of this inner bone edge, the angle of visualization and manipulation can significantly increase. In some cases, small osseous extensions of the orbital roof should also be removed carefully to allow excellent overview and easy introduction of microinstruments into the site. The dura should be opened in a curved fashion with its base toward the supraorbital rim. The free dural flap is fixed downwards with two sutures (Figure 6). Other dural elevation sutures are not required.

INTRADURAL DISSECTION

After opening the dura mater the first step should be drainage of cerebrospinal fluid by opening the chiasmatic and carotid cisterns. After removal of sufficient cerebrospinal fluid, the frontal lobe sinks spontaneously, making significant retraction of the frontal lobe unnecessary. Generally, the self-retaining spatula is left in place as a "brain protector" rather than a brain retractor.

DURA, BONE, AND WOUND CLOSURE

After completion of the intracranial procedure, the dural incision is closed watertight; interrupted or continuous sutures may be employed for this pur-

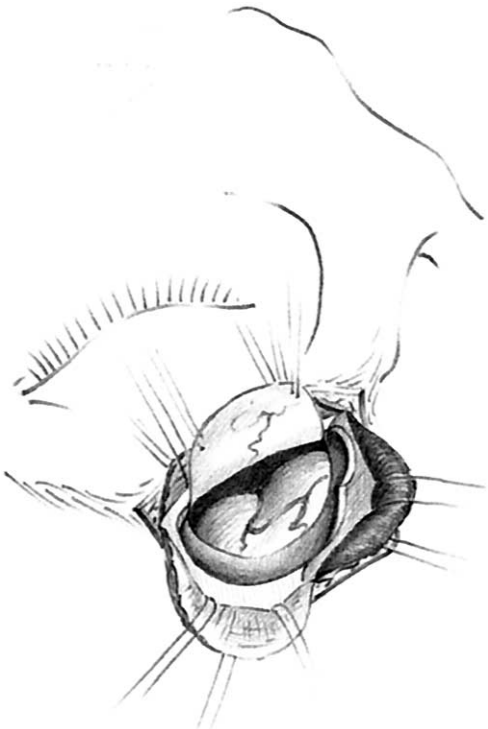

6 The dura should be opened in a curved fashion with its base toward the supraorbital rim. The free dural flap is fixed downwards with two sutures. Other dural elevation sutures are not required.

pose. A plate of gelfoam is placed extradurally; we do not suggest the use of fibrin glue due to the fibrinolytic effect of the cerebrospinal fluid. The bone flap is fixed with one titanium "Craniofix" plate (Aesculap AG, Tuttlingen, Germany). Note that the bone flap should be fixed medially and frontally without bony distance to achieve optimal cosmetic results. After final verification of hemostasis, the muscular and subcutaneous (layer is closed with interrupted sutures, the skin with running suture, sterile adhesive tape, or "Dermabond" glue (Johnson & Johnson, Somerville, New Jersey). Because of the small skin incision and atraumatic preparative technique, no suction drain is necessary.

TIPS AND TRICKS

In the following, we have collected ten simple tips and tricks offering easy handling during surgery. (1) Take time in the preoperative planning and positioning of patients to achieve an excellent overview of the target area and ergonomic working position. (2) Take care to determine anatomic orientation on the patient's head and use the three steps of marking with a sterile pen: osseuos structures and nerves → craniotomy → skin incision. (3) If the eyebrow is not dominant, the skin incision should be performed in a crease or scar of the supraorbital area. (4) The frontal muscle should be retracted upwards strongly with two or three sutures to achieve sufficient overview of the frontal bone; however, exposure of the frontal and orbital muscles downward to the supraorbital rim should be restricted to a necessary minimum to prevent postoperative periorbital hematoma. (5) Be careful during the burr hole trephination: correct placement but incorrect direction of drilling may penetrate the orbit. (6) Steps of craniotomy: burr hole trephination → frontobasal cutting parallel to the orbital rim → sawing in a semilunar fashion from burr hole to the medial edge of the first craniotomy line. (7) Drilling of the inner edge of the supraorbital rim after removal of the bone flap allows excellent overview and easy introduction of microinstuments to the site. (8) If necessary, small osseous extensions of the orbital roof should also be removed extradurally. (9) Open the dura in a C-shaped, semilunar fashion and direct the dural flap toward the supraorbital rim with two sutures. (10) Note the positioning of the bone flap during wound closure: it should be fixed medially and frontally without bony distance to achieve optimal cosmetic results.

Discussion

During recent decades a number of innovative neurosurgeons have been evolving Krause's pioneering work of the supraorbital subfrontal approach. In 1982, Jane described a supraorbital approach to tumors and aneurysms of the suprasellar area, as well as to orbital lesions [10]. Al-Mefty modified this approach by incorporating the superior and lateral orbital walls [1]; Delashaw described the temporal [5] and orbital extension [6] of the supraorbital exposure. The inferior extension of the supraorbital craniotomy by removal of the orbital rim was also described by Delfini using an alternative technique with two bone flaps [7]. Smith et al and Zabramsky et al published descriptions of extended temporal and orbitozygomatic bone removal providing wide access to the anterior and middle cranial fossa [14,18].

Most of these variations of the subfrontal and frontolateral approaches have required extensive soft tissue and bony exposure and brain retraction, potentially increasing surgical morbidity not related to the lesion itself. However, the enormous development of microneurosurgical techniques together with refined instrumentation and preoperative planning using the excellent preoperative diagnostic facilities available, enable neurosurgeons to

treat more complicated lesions through smaller and more specific approaches [13,17]. Similar to the pioneering presentation on a small frontolateral approach from Brock and Dietz in 1978 [2], the novel publications on the subfrontal exposures describe limited skin incision and soft tissue dissection with limited craniotomy and brain retraction, thus minimizing the intraoperative trauma to eloquent intracranial structures while allowing optimal cosmetic results [3,4,8,9,12,13,16,17].

In this report, we describe the surgical technique of the supraorbital key-hole craniotomy, based on our more than 10 years of experience. The described approach offers several advantages compared to standard craniotomies.

First, the limited supraorbital key-hole craniotomy allows minimal brain exposure to nonphysiologic surroundings such as room air, irrigation, cover material, or spatula pressure. Brain retraction is minimized or even eliminated, thus significantly decreasing approach-related morbidity and shortening hospitalization. With the key-hole concept, despite limited craniotomy and dural opening, deep-seated or even contralateral structures can be adequately visualized. The simple surgical exploration significantly reduces the length of the operation with a dural opening of approximately 10 min after skin incision. The short skin incision within the eyebrow and the single burr hole trephination behind the temporal line with correct fixation of the small bone flap during wound closure offer pleasing cosmetic results. Because of the limited skin incision and minimal soft tissue retraction, the superficial frontotemporal neurovascular structures such as the supraorbital nerve and artery, the frontal branch of the facial nerve and the superficial temporal artery are preserved. In addition, the minimal soft tissue and osseous dissection reduces postoperative orbital and frontotemporal swelling, and the excellent blood supply of the supraorbital area minimizes postoperative wound-healing disturbances.

We express special gratitude to Stefan Kindel for the artistic illustrations and to Janice Roberts for preparation of the manuscript.

REFERENCES

1. Al-Mefty O, Fox JL. Superolateral orbital exposure and reconstruction. Surg Neurol 1985;23:609–13.
2. Brock M, Dietz H. The small frontolateral approach for the microsurgical treatment of intracranial aneurysms. Neurochirurgia 1978;21:185–91.
3. Cohen AR, Perneczky A, Rodziewicz GS, Gingold SI. Endoscope-assisted craniotomy: approach to the rostral brain stem. Neurosurgery 1995;36:1128–30.
4. Czirják S, Szeifert Gy. Surgical experience with frontolateral keyhole craniotomy through a superciliary skin incision. Neurosurgery 2001;48:145–50.
5. Delashaw JB, Tedeschi H, Rhoton AL. Modified supraorbital craniotomy: technical note. Neurosurgery 1992;30:954–6.
6. Delashaw JB, Jane JA, Kassel NF, Luce C. Supraorbital craniotomy by fracture of the anterior orbital roof. Technical note. J Neurosurg 1993;79:615–8.
7. Delfini R, Raco A, Artico M, Salvati M, Ciappetta P. A two-step supraorbital approach to lesions of the orbital apex. Technical note. J Neurosurg 1992;77:959–61.
8. Fries G, Perneczky A, van Lindert E, Bahadori-Mortawasi F. Contralateral and ipsilateral microsurgical approach to carotid-ophtalmic aneurysms. Neurosurgery 1997;41:333–43.
9. Fries G, Perneczky A. Endoscope-assisted keyhole surgery for aneurysms of the anterior circulation and the basilar apex. Operative Tech Neurosurg 2000; 3(4):216–30.
10. Jane JA, Park TS, Pobereskin LH, Winn HR, Butler AB. The supraorbital approach: technical note. Neurosurgery 1982;11:537–42.
11. Krause F. Chirurgie des Gehirns und Rückenmarks nach eigenen Erfahrungen. Berlin: Urban und Schwarzenberg, 1908.
12. Menovsky T, Grotenhuis A, de Vries J, Bartels RHMA. Endoscope-assisted supraorbital craniotomy for lesions of the interpeduncular fossa. Neurosurgery 1999;44:106–12.
13. Perneczky A, Fries G. Endoscope-assisted brain surgery: Part 1—evolution, basic concept, and current technique. Neurosurgery 1998;42:219–25.
14. Smith RR, Al-Mefty O, Middleton TH. An orbitocranial approach to complex aneurysms of the anterior circulation. Neurosurgery 1989;24:385–91.
15. Steiger HJ, Schmid-Elsaesser R, Stummer W, Uhl E. Transorbital key-hole approach to anterior communicating artery aneurysms. Neurosurgery 2001;48: 347–52.
16. van Lindert E, Perneczky A, Fries G, Pierangeli E. The supraorbital keyhole approach to supratentorial aneurysms: concept and technique. Surg Neurol 1998; 49:481–90.
17. Wilson DH. Limited exposure in cerebral neurosurgery. Technical note. J Neurosurg 1971:102–6.
18. Zabramsky JM, Kiris T, Sankhla SK, Caniol J, Spetzler RF. Orbitozygomatic approach. Technical note. J Neurosurg 1998;89:336–341.