The Minimally Invasive Supraorbital Subfrontal Key-Hole Approach for Surgical Treatment of Temporomesial Lesions of the Dominant Hemisphere

Authors R. Reisch[1,5], A. Stadie[2], R. Kockro[1], I. Gawish[3], E. Schwandt[2], N. Hopf[4]

Affiliations Affiliation addresses are listed at the end of the article

Key words
- eyebrow skin incision
- minimally invasive neurosurgery
- preoperative planning
- supraorbital approach
- temporomesial lesions

Abstract

Introduction: Surgery in the temporomesial region is generally performed using a subtemporal, transtemporal, or pterional-transsylvian approach. However, these approaches may lead to approach-related trauma of the temporal lobe and frontotemporal operculum with subsequent postoperative neurological deficits. Iatrogenic traumatisation is especially significant if surgery is performed in the dominant hemisphere.

Methods: During a five-year period between January 2003 and December 2007, we have approached the temporomesial region in 21 cases via the supraorbital approach. In 15 cases, the lesion was located within the dominant hemisphere, all lesions had space-occupying effects. In all cases, meticulous approach planning was performed, demonstrating a close proximity of the lesion to the pial surface on the upper anterior mesial aspect of the temporal lobe. An extension within the parahippocampal gyrus or with deep temporobasal tumor growth below the sphenoid wing were considered as exclusion criteria for using the supraorbital approach.

Results: In all cases surgery was performed without intraoperative complications. Pathological investigation showed 7 low-grade astrocytomas, 4 high-grade astrocytomas, 2 gangliogliomas and 2 cavernomas. Early postoperative MRI scans confirmed a complete removal of the lesion in 14 cases. In one case of a subtotal resection, the residual tumor was removed through a posterior subtemporal approach. The postoperative neurological examination was unchanged in 14 cases. In one case a transient hemiparesis was observed. In patients with dominant-sided lesions no speech or mental deficits were present.

Conclusion: In selected cases, the minimally invasive supraorbital craniotomy offers excellent surgical efficiency in the temporomesial region with no approach-related morbidity compared to a standard transtemporal or pterional-transsylvian approach.

Bibliography
DOI 10.1055/s-0029-1238285
Minim Invas Neurosurg 2009; 52: 163–169

ISSN 0946-7211

Correspondence
Prof. R. Reisch, MD, PhD
Centre of Endoscopic and Minimally Invasive Neurosurgery
Clinic Hirslanden Zurich
Witellikerstraße 40
8032 Zurich
Switzerland
Tel.: +41 44387 2111
robert.reisch@gmail.com

Introduction

Temporomesial lesions comprise a common dilemma for surgical resection, especially if located within the dominant side [1–4]. As a general rule, subtemporal, transtemporal or pterional-transsylvian approaches are used to expose the temporomesial area; however, these approaches may result in surgical traumatization of the frontal or temporal lobe, not related to the lesion itself [5–7]. This iatrogenic traumatization of eloquent neural tissue may cause severe postoperative neurological deficits [8–10].

However, critical analysis of the anatomic relationship of the temporal lobe to the skull base reveals that the temporomesial area can effectively be exposed from the anterior subfrontal direction. Compared with the subtemporal, transtemporal and pterional-transsylvian approaches, the subfrontal route offers optimal exposure of the anterio-superior temporomesial structures without transcortical access and without the necessity to open the Sylvian fissure (**Fig. 1**). Thus, intracranial lesions located within the anterio-superior mesial part of the temporal lobe may sufficiently be approached through a subfrontal supraorbital craniotomy, without retraction and injury of the frontotemporal operculum and temporal cortex.

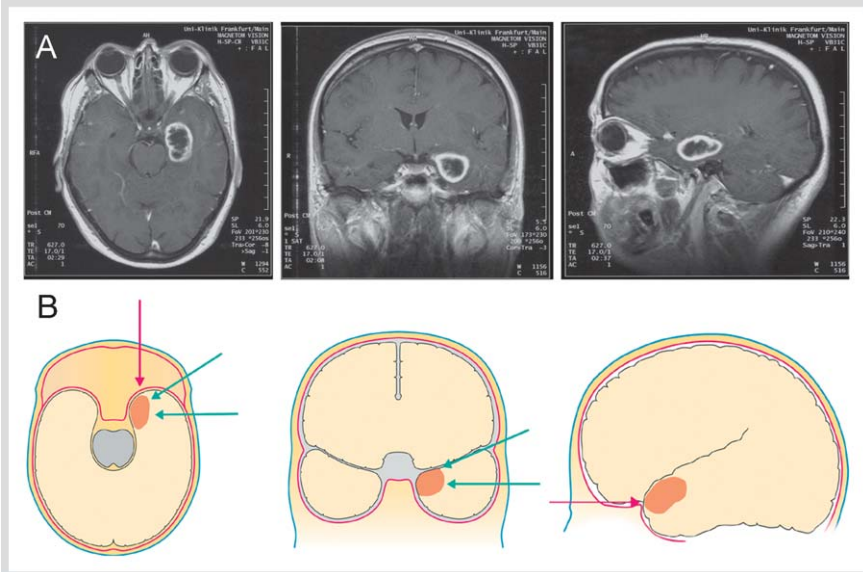

Fig. 1 Schematic drawings showing the relationship of the temporomesial region to the frontotemporal skull base compared with one of the surgical cases (Pat No. 6, 60/F). Note that exposing from the subfrontal direction, (red arrow), the anterior temporomesial area can sufficiently be approached without approach-related traumatization of the eloquent lateral temporal cortex and frontolateral operculum. Limited approach-related damage is critical in dominant-sided lesions, thus avoiding postoperative deterioration (Special thanks to Stefan Kindel for his creative support in ▶ Figs. **1** and **2**).

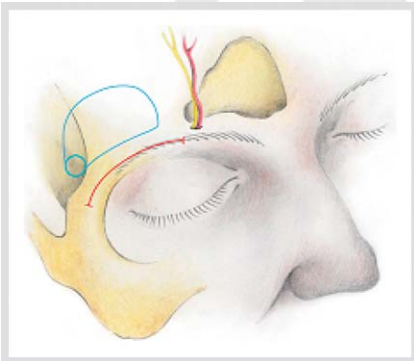

Fig. 2 Artist's drawing demonstrating the limited supraorbital craniotomy in comparison with anatomic landmarks of the frontolateral area. The skin incision is performed laterally from the supraorbital foramen, within the eyebrow. After a frontobasal burr hole trephination, a bone flap is made, creating a keyhole craniotomy.

In this article, we describe our surgical experience with patients suffering from antero-superior located temporomesial lesions of the dominant hemisphere, treated successfully via a subfrontal supraorbital approach (▶ **Fig. 2**). After precise preoperative planning, the supraorbital craniotomy was performed in selected cases with lesions showing a close proximity to the pial surface only on the anteromesial surface of the temporal lobe.

Patients and Methods

Between January 2003 and December 2007, we have used the supraorbital subfrontal approach in 15 cases, exposing various temporomesial lesions (▶ **Table 1**). This clinical series was evaluated retrospectively, reviewing office charts, medical reports and diagnostic images.

We operated 9 female and 6 male patients. The age range of the patients was from 19 years to 64 years.

The predominant preoperative clinical finding was epileptic seizure in 13 of 15 patients, one patient revealed mild hemiparesis. An initial clinical examination without pathological findings was found in 2 of 15 cases.

In all cases, for precise preoperative planning high-resolution cranial magnetic resonance imaging (MRI) and computed tomography (CT) were carried out. In 4 cases the individual pathoanatomic situation was preoperatively analyzed using a virtual reality (VR) workstation (Dextroscope of Volume Interactions Pte Ltd., Singapore). We used this technology of VR surgery planning in those cases where successful surgery seemed critical using a supraorbital approach.

The criterion for using the supraorbital subfrontal exposure was a strict anterior temporomesial localization of the lesion, demonstrating a close proximity to the pial surface on the upper anterior mesial aspect of the dominant hemispheric temporal lobe. A posterior mesial or deep temporobasal extension below the sphenoid wing was an exclusion criterion for this approach.

The supraorbital approach was only performed when the analysis of the preoperative images depicted clearly that a complete resection of the lesion could be achieved, allowing a maximally effective and minimally invasive surgical therapy.

Surgical technique demonstrated by an illustrative case

This 37-year-old woman was admitted to a neurological department after an epileptic seizure. The neurological examination revealed no deficits. Initial diagnostics included a contrast-enhanced MRI of the brain showing a left sided temporal cavernoma (▶ **Fig. 3A**). For exact preoperative planning of the optimal surgical exposure, the MRI and CT data were transferred to a virtual reality workstation.

The three-dimensional VR planning revealed a close proximity of the lesion to the cortical surface of the anterosuperior temporomesial area (▶ **Fig. 4**), allowing safe and effective exposure via a subfrontal approach. According to increasing epileptic seizures and space-occupying effects, the indication for surgery was given. The removal of the lesion was supplemented by using intraoperative neuronavigation (BrainLAB, Feldkirchen, Germany).

The patient was placed in a supine position, the head elevated approximately 15°, rotated 15° to the opposite side and retroflected about 20°. The head elevation facilitated venous drainage; the moderate rotation offered an ergonomic working position during surgery and optimal exposure of the ipsilateral

Table 1 Patients presentation.

Age, sex	Preoperative neurological status	Postoperative neurological status	Tumor removal	Histopathology	Size	Location of the lesion	Structure of the lesion
33, F	seizures	no deficit	complete	astrocytoma II.	2 cm	uncus	sol
44, F	seizures	no deficit	residual tumor	astrocytoma III.	4 cm	PH gyrus	sol > cys
26, M	NPF	no deficit	complete	astrocytoma II.	2.5 cm	uncus	sol > cys
29, M	seizures	no deficit	complete	astrocytoma II.	2 cm	MTP	sol > cys, HV
43, F	seizures HP	no deficit	complete	astrocytoma III.	4 cm	TM	sol, HV
60, F	seizures	no deficit	PC, recurrence	glioblastoma	3 cm	uncus	cys > sol
64, M	NPF	no deficit	complete	astrocytoma II.	3 cm	MTP	sol, HV
51, F	seizures	no deficit	complete	astrocytoma II.	3.5 cm	TM	sol > cys
22, M	seizures	no deficit	PC, recurrence	glioblastoma	3 cm	MTP	cys > sol, HV
31, M	seizures	no deficit	complete	astrocytoma II.	1.5 cm	uncus	sol > cys
19, F	seizures	temp HP	complete	ganglioglioma	2 cm	TM	sol = cys
44, F	seizures	no deficit	complete	cavernoma	3 cm	TM	sol
39, M	seizures	no deficit	complete	ganglioglioma	2.5 cm	TM	sol
56, F	seizures	no deficit	complete	astrocytoma II.	3 cm	MTP	sol > cys
37, F	seizures	no deficit	complete	cavernoma	4 cm	uncus	lobulated

Abbreviations: cys = cystic; F = female; HP = hemiparesis; HV = highly vascularized; M = male; MTP = medial temporopolar; NPF = no pathological findings; PC = primary complete; PH = parahippocampal; sol = solid; temp = temporal; TM = temporomesial

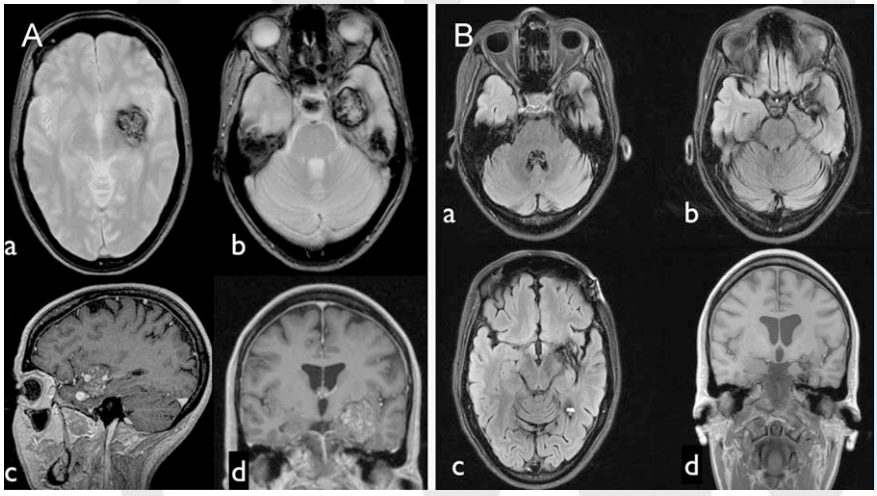

Fig. 3 MRI showing a temporomesial located cavernoma of the left dominant side (**A**). After surgery, no residual cavernoma could be detected (**B**). Patients postoperative course was uneventful: note undamaged appearance of the left dominant and temporal operculum. The supraorbital subfrontal access allowed optimal surgical exposure, thus avoiding approach related injury of these eloquent structures (Imaging was performed in the Department of Neuroradiology, Johannes Gutenberg-University, Mainz. Courtesy of Prof. W. Müller-Forell).

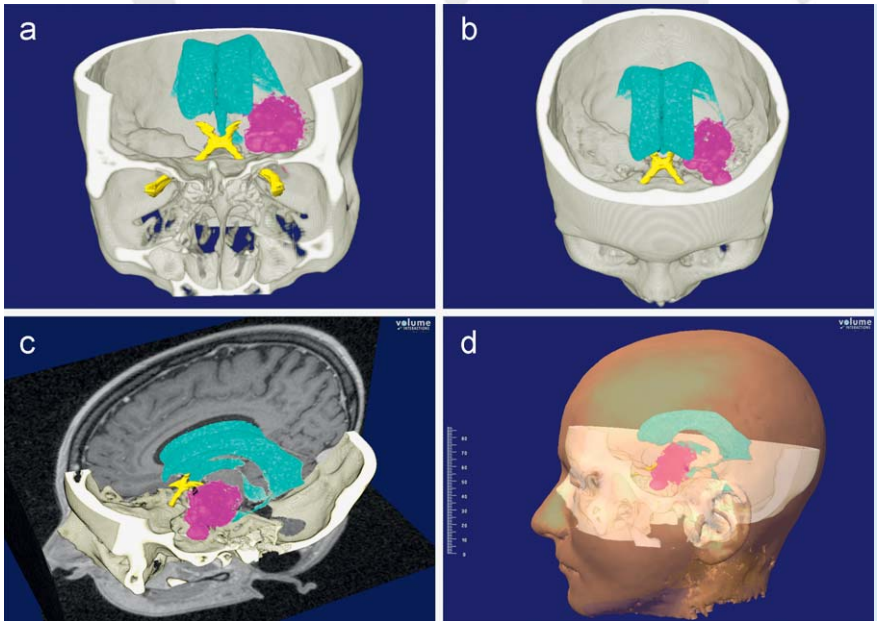

Fig. 4 Three-dimensional presentation of the cavernoma. Using virtual reality workstation, the optimal surgical way could be analyzed and defined. Note the relationship of the cavernoma (purple) to the ventricles (green), optic nerves (yellow) and to the bony skull base in an anterior (**a**) and anterior-superior (**b**) view. Special attention should be given to the sphenoid wing and to temporobasal extension of the lesion (**c**). Lateral view with additional visualization of the skin surface (**d**) offers exact planning of the tailored minimal invasive approach.

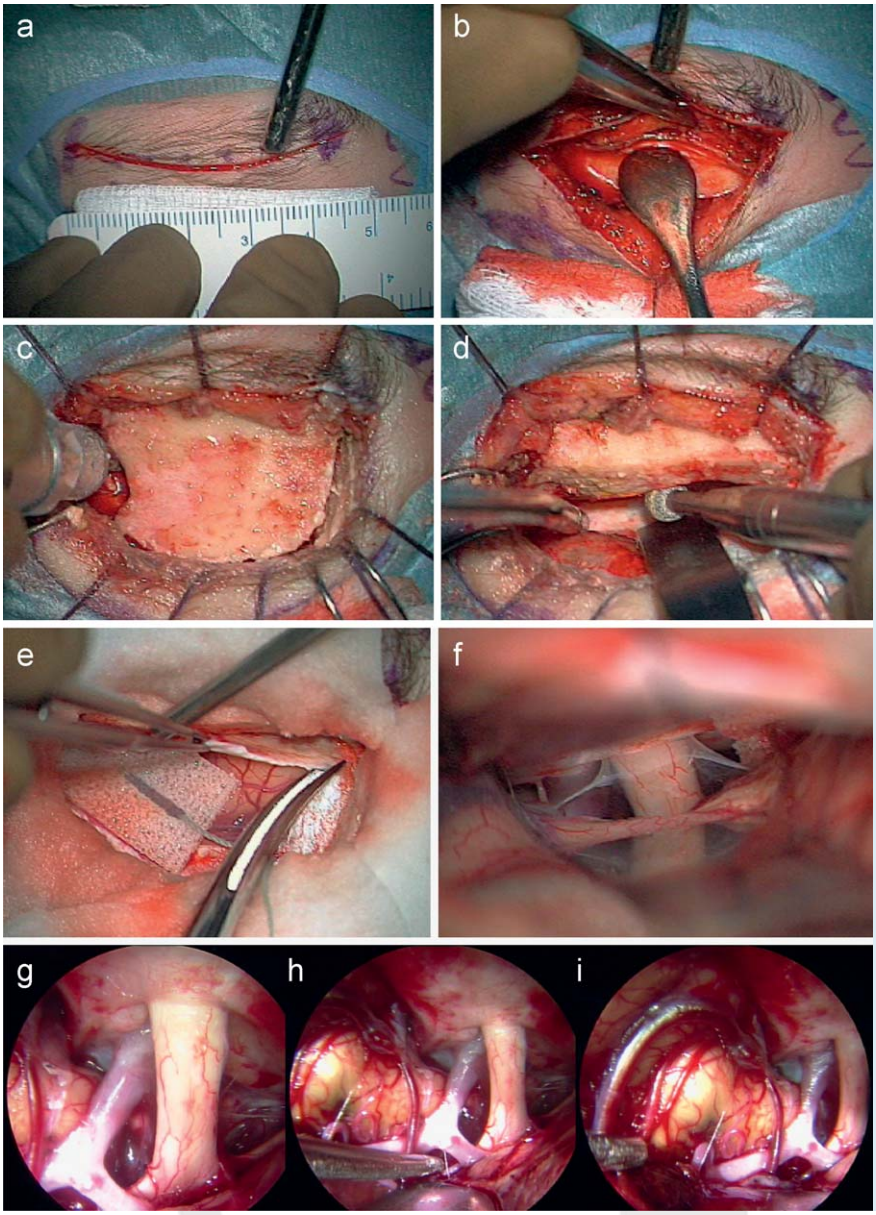

Fig. 5 Surgical steps for a left sided supraorbital craniotomy used for resection of a temporomesial located cavernoma. Creating the supraorbital approach, skin incision follows the orbital rim within the eyebrow, thus achieving satisfying cosmetic result (**a**). After cutting the frontal muscle with a monopolar knife in a medial to lateral course, the incision follows the temporal line in the basal direction. In this way, the temporal muscle is stripped from its boney insertion at the zygomatic process of the frontal bone, allowing mobilization of the muscles with periostal dissector (**b**). After muscular dissection and performing a single frontobasal burr hole, a limited frontolateral craniotomy is created with an extension of approximately 2.5 × 3.5 cm (**c**). A very important stage of the craniotomy after removal of the bone flap is high-speed drilling of the inner edge of the bone above the orbital rim under protection of the dura. Careful removal of this inner bone edge can significantly increase the angle for visulization and manipulation (**d**). Next, the dura is opened in a simple "C" shaped from while protecting the cortical surface and retracted in a basal direction (**e**). After gentle mobilization of the frontal lobe, the left optical nerve is approached. Note appearance of the carotid artery left from the optic nerve after partial opening of the cisterns with removal of cerebrospinal fluid (**f**). After further dissection of the cisterns, a 4 mm 0° endoscope is introduced into the surgical field for optimal visualization of the field. Note endoscopic appearance of the left optic nerve and carotid artery, compared with the microscopic visualisation (**f, g**). Moving the endoscope more in lateral direction, the carotid bifurcation, frontobasal cortex and the temporal pole appear. Behind the sucker the partially opened Sylvian fissure can be seen (**h**). Note the yellowish temporopolar cortical surface according to the exact localization of the cavernoma (**i**).

temporomesial region. The retroflexion supported gravity-related retropulsion of the frontal lobe.

The skin incision was started laterally from the supraorbital incisura within the eyebrow. To achieve a cosmetically optimal result, the incision followed the orbital rim (▶ **Fig. 5a**). After skin incision, the subcutaneous dissection was continued in the frontal direction to achieve optimal exposure of the fronto-lateral supraorbital area. The frontal muscle was then cut with a monopolar knife parallel to the orbital rim in a medial to lateral direction. The cutting then followed the temporal line in a basal direction to the zygomatic process of the frontal bone. In this way, the frontozygomatic part of the temporal muscle was stripped from its bony insertion; the muscles were mobilized with periostal dissector (▶ **Fig. 5b**). After muscular dissection, a single frontobasal burr hole was made using a high-speed drill. After minimal enlargement of the hole with a small punch and mobilization of the dura, a C-shaped line was cut with a high-speed craniotome defining the size and form of the craniotomy. Thereafter a straight line was created parallel to the orbital rim in a lateral to medial direction, taking into account the previously performed C-shaped line (▶ **Fig. 5c**). A very important stage of the craniotomy after removal of the bone flap was high-speed drilling of the inner edge of the bone above the orbital rim under protection of the dura. Careful removal of this inner bone edge can significantly increase the angle for visualization and manipulation. Small osseous extensions of the superficial orbital roof, so-called juga cerebralia, were drilled extradurally to obtain optimal intradural visualisation (▶ **Fig. 5d**). Thereafter, the dura was opened in a simple C-shaped form and retracted in a basal direction (▶ **Fig. 5e**).

Cerebrospinal fluid was removed by opening the carotid cisterns, exposing the internal carotid artery and optic nerve (▶ **Fig. 5f**). Thereafter, the medial part of the Sylvian fissure was opened in a medial to lateral direction. An endoscope was then introduced into the surgical field for optimal visualization (Aesculap AG, Tuttligen, Germany). Note the appearance of the chiasmatic cistern (▶ **Fig. 5g**) and the left carotid artery and optic nerve (▶ **Fig. 5h**). Moving more in a lateral direction, the temporal pole was observerved. Note the yellowish cortical surface according to the exact localization of the cavernoma (▶ **Fig. 5i**). Using this technique, the temporopolar and temporomesial regions were effectively exposed from the anterior subfrontal

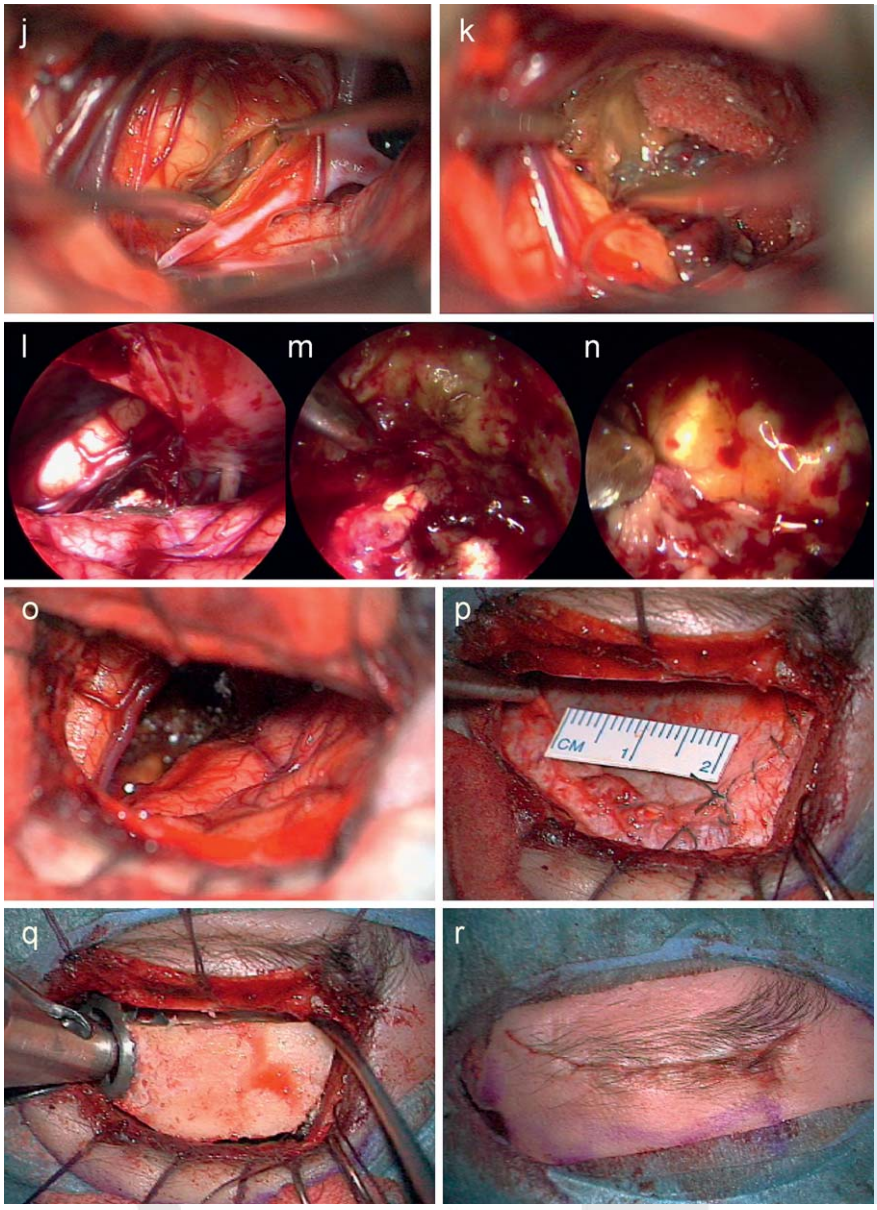

Fig. 5 (Continued) After endoscopic orientation, the operation was continued in microsurgical technique, exposing the anterior surface of the cavernoma (**j**). The temporal veins and the middle cerebral artery with its critical perforators are not injured by the subfrontal dissection. According to the ideal surgical exposure, the lesion could be dissected from the surrounding brain tissue effortlessly (**k**). After complete removal of the lesion, the field is again observed with the 0° endoscope. Note the untouched eloquent lateral temporal and frontobasal cortical surface (**l**). Exposing the cavity of resection in close-up position, no residual cavernoma could be detected; for observation of hidden parts of the field, a 30° endoscope was used (**m**). Note the choroid plexus of the lateral ventricle and yellowish surface of the hippocampus (**n**). After finishing of the intracranial procedure and adequate hemostasis (**o**), the dura mater is closed with watertight sutures. Note the size of the dural opening, according to the limited craniotomy (**p**). The bone flap is re-implanted and fixed with Cranio-Fix (B. Braun/Aesculap, Tuttlingen, Germany) plates. Note that the primary burr hole is closed with the plate and the bone flap tightly fixed both medially and frontally to achieve optimal cosmetic results (**q**). After final verification of haemostasis, the muscular and subcutaneous layers are closed with interrupted sutures and the skin with intracutaneous sutures (**r**). According to the minimal osteomuscular destruction, no suction drain is used.

direction, without approach-related traumatization of the Sylvian veins, the eloquent frontotemporal operculum and the temporal lobe. Endoscopic images demonstrated the four main advantages of endoscopes including increased light intensity, extended viewing angle with potential direct visualization of hidden parts of the field and clear depiction of details in close-up positions. After endoscopic orientation, the operation was continued in a microsurgical technique, exposing the anterior surface of the cavernoma (▶ **Fig. 5j**). According to the ideal surgical exposure, the lesion could be dissected from the surrounding brain tissue effortlessly (▶ **Fig. 5k**). After complete removal of the lesion, the field was again observed with the endoscope. Note the untouched eloquent lateral temporal cortical surface (▶ **Fig. 5l**). Exposing the cavity of resection, no residual cavernoma could be detected (▶ **Fig. 5m**). Note the choroid plexus of the lateral ventricle (▶ **Fig. 5n**). After finishing of the intracranial procedure and adequate hemostasis (▶ **Fig. 5o**) the dura mater was closed with interrupted sutures. Note the size of the dural opening (▶ **Fig. 5p**). The bone flap was re-implanted and fixed with Cranio-Fix plates (B. Braun/Aesculap, Tuttlingen, Germany). Note the optimum placement of the bone flap for an adequate cosmetic outcome (▶ **Fig. 5q**). After final verification of hemostasis, the muscular and subcutaneous layers were closed with interrupted and the skin with intracutaneous sutures.

After surgery the patient was observed overnight in the neurosurgical intensive care unit, neurological examination revealed no pathological findings. Especially no speech or cognitive deficits could be exposed. The early postoperative contrast enhanced MRI 24 h after surgery revealed the complete resection of the cavernoma (▶ **Fig. 3B**). Four weeks after surgery the patient returned to her previous employment. Six months postoperatively the anticonvulsive therapy was stopped, without recurrent seizures.

Results

▼

In 14 patients, the anterosuperior localized temporomesial lesions could be safely and effectively exposed via the supraorbital craniotomy without traumatization of the eloquent dominant temporolateral cortex. The early postoperative MRI revealed

in 14 cases complete tumour removal, in 1 case subtotal resection could be detected. In this case, the posterior aspect of the tumor within the parahippocampal gyrus could not be removed; a re-operation was made through a posterior subtemporal-transtemporal approach and complete tumor removal was achieved. No intraoperative complications occurred, re-modelling of the craniotomy was not necessary.

The postoperative neurological examination revealed a transient hemiparesis in one patient; in this case the tumor reached the lateral aspect of the cerebral peduncule; however, the patient was neurologically intact at discharge. In all other patients no neurological deficits were observed, especially, neither speech deficits nor memory disturbances could be observed.

There were no surgical complications during the postoperative period; cerebrospinal fluid fistulas or wound healing disturbances could not be observed. In all cases the cosmetic outcome was excellent.

Pathological investigations showed 7 low-grade astrocytomas, 4 high-grade astrocytomas, 2 gangliogliomas and 2 cavernomas. The patients with glioblastomas received postoperative radiotherapy and chemotherapy according to the EORTC protocoll (**Table 1**).

Discussion

Although the temporomesial region can be surgically exposed via subtemporal, transtemporal or pterional-transsylvian approaches, the traumatization of the eloquent dominant temporal lobe and retraction of the frontotemporal operculum can subsequently cause postoperative neurological deterioration among patients [6, 10–12]. Gleissner pointed out a functional association of verbal memory with the left-sided temporal lobe, on operating pediatric and adult patients with temporal lobe epilepsy [8]. Helmstaedter described significant memory impairment with negative effects on learning and consolidation/retrieval after left anterior temporal lobectomy [9]. Clusmann reported on more beneficial neuropsychological results after surgical resections limited to a temporal lesion itself without traumatization of the surrounding brain tissue [13]. These occasionally severe symptoms of speech, memory and cognitive disorders are inacceptable if the target area can also be exposed via a different, less invasive but comparably effective approach.

The reduction of brain exploration and retraction is essential, exposing dominant hemispheric temporomesial structures [3, 4]. With the knowledge of specific anatomic details of an individual patient, an individual surgical procedure can be performed to reducing the size of the craniotomy, the extent of brain surface exploration, and retraction to a necessary minimum limit [14–17].

The subfrontal exposure was first published by Fedor Krause in the first volume of his pioneering work "Surgery of the Brain and Spine", published in 1908 [18]. Although his operation was rough and traumatic according to the undeveloped macrosurgical techniques of that time, Krause has already realized the potential of the subfrontal exposure, namely the free surgical access from an anterior direction to the suprasellar and medial temporal structures without dissection and retraction of the temporal lobe.

During the last decades, a variety of subfrontal approaches have been described in the neurosurgical literature, although differently named the exposures were in the fact quite similar. Brock published in 1978 a revolutionary minimally invasive concept approaching aneurysms of the anterior circulation via a limited lateral subfrontal craniotomy [19]. In 1982 Jane reported a supraorbital exposure to aneurysms and other lesions of the suprasellar area as well as to orbital lesions [20]. This approach was modified by Delashaw to involve fracturing the orbital roof or including a temporal extension of the craniotomy [21, 22]. The inferior extension of the supraorbital craniotomy by removal of the orbital rim was also described by Delfini using an alternative technique with two bone flaps [23]. Al-Mefty published his experience concerning a supraorbital-pterional approach, Smith described extended temporal and orbitozygomatic bone removal [24, 25].

Recent publications on the subfrontal exposures describe limited skin incision and soft tissue dissection with limited craniotomy and brain retraction in accord with the enormous development of diagnostic facilities and neurosurgical techniques [14, 26–29]. In 1998 van Lindert reported surgical experience using a supraorbital subfrontal craniotomy with eyebrow skin incision for the treatment of 197 intracranial aneurysms, Czirják published his experiences in 2001 and 2002, Ramos-Zúniga presented a transsupraorbital approach [29–32]. In 2001, Steiger described his small orbitocranial approach through a frontotemproral hairline incision, approaching aneurysms of the anterior communicating artery [33].

We have demonstrated the concept and surgical technique of the supraorbital keyhole approach using minimally invasive techniques [34–36]. In 2005, our ten-year expertise with the supraorbital subfrontal approach through an eyebrow skin incision was summarized [37]. Recently, our experience with aneurysms of the middle cerebral artery was reported, thus treating bilateral aneurysms through unilateral supraorbital approach [38].

In this clinical series, we could demonstrate that anterosuperior located temporomesial lesions of the dominant hemisphere can effectively be approached through a limited supraorbital keyhole craniotomy. In 14 of 15 cases complete removal of the lesion was achieved. The supraorbital key-hole approach allowed adequate exposure and safe resection of dominant hemispheric antero-superior situated temporomesial lesions, according to the concepts of minimally invasive key-hole neurosurgery. No postoperative mortality and no permanent morbidity could be observed in our 15 patients, especially no verbal or memory disturbances due to the absence of traumatization of the dominant temporal lobe and frontotemporal operculum.

Still, we identified limits for this surgical technique. The supraorbital approach was only used in cases with a strict anterior temporomesial localization of the lesion. A posterior mesial extension of the lesion within the parahippocampal gyrus or a deep temporobasal tumor growth below the sphenoid wing seemed to limit the feasibility of the supraorbital approach.

However, using neuronavigation and endoscopes, the utility of the supraorbital key-hole approach can successfully be extended. To the best of our knowledge there has been no previous report of temporomesial lesions exposed and treated successfully using a supraorbital craniotomy.

Only a limited number of patients could be included in this study, because of the meticulous preoperative planning and selection of patients necessary to justify the feasibility of the approach. Further data collections with more surgical cases are required to evaluate the effectiveness of the supraorbital cranio-

tomy in patients with dominant hemisphere temporomesial lesions.

Conclusions

The supraorbital key-hole approach allowed adequate exposure and safe resection of dominant hemispheric anterosuperior situated temporomesial gliomas, according to the concept of the minimally invasive key-hole neurosurgery.

Acknowledgements

We gratefully acknowledge the constant and inspiring support of our former chairman and teacher Axel Perneczky. He died in a tragic way; his pupils will never forget him.

Affiliations

[1] Neurosurgical Department, University Hospital Zurich, Zurich, Switzerland
[2] Department of Neurosurgery, Johannes-Gutenberg University Mainz, Mainz, Germany
[3] Department of Neurosurgery, Klinikum Nordstadt, Hannover, Germany
[4] Department of Neurosurgery, Katharinenhospital, Stuttgart, Germany
[5] Centre of Endoscopic and Minimally Invasive Neurosurgery, Clinic Hirslanden, Zurich, Switzerland

References

1 *Jorge CL, Nagahashi-Marie SK, Pereira CC et al.* Clinical characteristics and surgical outcome of patients with temporal lobe tumors and epilepsy. Arq Neuropsiquiart 2000; 58: 1002–1008
2 *Schramm J, Kral T, Grunwald T et al.* Surgical treatment for neocortical temporal lobe epilepsy: clinical and surgical aspects and seizure outcome. J Neurosurg 2001; 94: 33–42
3 *Smith KA, Spetzler RF.* Supratentorial-infraoccipital approach for posteromedial temporal lobe lesions. J Neurosurg 1995; 82: 940–944
4 *Yonekawa Y, Imhof HG, Taub E et al.* Supracerebellar transtentorial approach to posterior temporomedial structures. J Neurosurg 2001; 94: 339–345
5 *Otsubo H, Hoffman HJ, Humpreys RP et al.* Evaluation, surgical approach and outcome of seizure in patients with gangliogliomas. Pediatr Neurosurg 1990; 16: 208–212
6 *Santoro A, Salvati M, Frati A et al.* Surgical approaches to tumors of the lateral ventricles in the dominant hemisphere. J Neurosurg Sci 2002; 46: 60–65
7 *Vajkoczy P, Krakow K, Stodieck S et al.* Modified approach for selective treatment of temporal lobe epilepsy: transsylvian-transcisternal mesial en bloc resection. J Neurosurg 1998; 88: 855–862
8 *Gleissner U, Sassen R, Lendt M et al.* Pre- and postoperative verbal memory in pediatric patients with temporal lobe epilepsy. Epilepsy Res 2002; 51: 287–296
9 *Helmstaedter C, Reuber M, Elger C.* Interaction of cognitive aging and memory deficits related to epilepsy surgery. Ann Neurol 2002; 52: 89–94
10 *Hori T, Tabuchi S, Kurosaki M et al.* Subtemoral amygdalohippocampectomy for treating medical intractable temporal lobe epilepsy. Neurosurgery 1993; 33: 50–56
11 *Andoh T, Shinoda J, Miwa Y et al.* Tumors at the trigone of the lateral ventricle – clinical analysis of eight cases. Neurol Med Chir 1990; 30: 676–684
12 *Arita K, Kurisu K, Iida K et al.* Surgical treatment for intractable epilepsy caused by cavernous angioma in the temporal lobe of the dominant hemisphere – three case reports. Neurol Med Chir 2000; 40: 439–445
13 *Clusmann H, Schramm J, Kral T et al.* Prognostic factors and outcome after different types of resection for temporal lobe epilepsy. J Neurosurg 2002; 97: 1131–1141
14 *Fries G, Perneczky A.* Endoscope-assisted keyhole surgery for aneurysms of the anterior circulation and the basilar apex. Operative Techniques in Neurosurgery 2000; 3: 216–230
15 *Perneczky A.* Planning strategies for the suprasellar region. Philosophy of approaches. Neurosurgeons 1992; 11: 343–348
16 *Perneczky A, Fries G.* Endoscope-assisted brain surgery: Part 1 – Evolution, basic concept, and current technique. Neurosurgery 1998; 42: 219–225
17 *Perneczky A, Müller-Forell W, van Lindert E et al* Keyhole Concept in Neurosurgery. Stuttgart, New York: Thieme Medical Publishers; 1999
18 *Krause F.* Chirurgie des Gehirns und Rückenmarks nach eigenen Erfahrungen. Vol. 1. Urban & Schwarzenberg, Berlin; 1908
19 *Brock M, Dietz H.* The small frontolateral approach for the microsurgical treatment of intracranial aneurysms. Neurochirurgia 1978; 21: 185–191
20 *Jane JA, Park TS, Pobereskin LH et al.* The supraorbital approach: Technical note. Neurosurgery 1982; 11: 537–542
21 *Delashaw JB, Tedeschi H, Rhoton AL.* Modified supraorbital craniotomy: Technical note. Neurosurgery 1992; 30: 954–956
22 *Delashaw JB, Jane JA, Kassel NF et al.* Supraorbital craniotomy by fracture of the anterior orbital roof. Technical note. J Neurosurg 1993; 79: 615–618
23 *Delfini R, Raco A, Artico M et al.* A two-step supraorbital approach to lesions os the orbital apex. Technical note. J Neurosurg 1992; 77: 959–961
24 *Al-Mefty O.* The supraorbital-pterional approach to skull base lesions. Neurosurgery 1987; 21: 474–477
25 *Smith RR, Al-Mefty O, Middleton TH.* An orbitocranial approach to complex aneurysms of the anterior circulation. Neurosurgery 1989; 24: 385–391
26 *Cohen AR, Perneczky A, Rodziewicz GS et al.* Endoscope-assisted craniotomy: Approach to the rostral brain stem. Neurosurgery 1995; 36: 1128–1130
27 *Fries G, Perneczky A.* Endoscope-assisted brain surgery: Part 2 – Analysis of 380 procedures. Neurosurgery 1998; 42: 226–232
28 *Menovsky T, Grotenhuis A, de Vries J et al.* Endoscope-assisted supraorbital craniotomy for lesions of the interpeduncular fossa. Neurosurgery 1999; 44: 106–112
29 *van Lindert E, Perneczky A, Fries G et al.* The supraorbital keyhole approach to supratentorial aneurysms: Concept and technique. Surg Neurol 1998; 49: 481–490
30 *Czirják S, Szeifert Gy.* Surgical experience with frontolateral keyhole craniotomy through a superciliary skin incision. Neurosurgery 2001; 48: 145–150
31 *Czirják S, Nyáry I, Futó J et al.* Bilateral supraorbital keyhole approach for multiple aneurysms via superciliary skin incision. Surg Neurol 2002; 57: 314–324
32 *Ramos-Zúniga R, Velázquez H, Barajas M et al.* Trans-supraorbital approach to supratentorial aneurysms. Neurosurgery 2002; 51: 125–131
33 *Steiger HJ, Schmid-Elsaesser R, Stummer W et al.* Transorbital key-hole approach to anterior communicating artery aneurysms. Neurosurgery 2001; 48: 347–352
34 *Perneczky A, Reisch R.* Key Hole Approaches in Neurosurgery. Volume I. Concept and surgical technique. Springer Verlag Wien; 2008, ISBN: 978-3-211-83885-3
35 *Reisch R, Perneczky A, Filippi R.* Surgical technique of the supraorbital key-hole craniotomy. Surg Neurol 2003; 59: 223–227
36 *Reisch R, Perneczky A.* The Supraorbital craniotomy for frontobasal meningeomas. In Kobayashi (ed): Neurosurgery of Complex Vascular Lesions and Tumors. Thieme Verlag Stuttgart New York; 2005, pp: 201–206
37 *Reisch R, Perneczky A.* Ten-year experience with the supraorbital subfrontal approach through an eyebrow skin incision. Neurosurgery 2005; 57: 242–255
38 *Hopf N, Stadie A, Reisch R.* Surgical management of bilateral middle cerebral artery aneurysms via a unilateral supraorbital key-hole craniotomy. Minim Invasive Neurosurg 2009; 52: 126–131