Journal of Neurosurgery Publishing Group
Page Proof Policy

Your manuscript has been edited for content, consistency, and JNSPG style. Please be advised that all papers are run through a pre-editing program. Among other functions, the program converts British English to American English in all areas of the paper except the reference section. In a manuscript in which a declarative title was used, the title is reworked to avoid the declarative.

- **PLEASE REVIEW THE PAGE PROOFS CAREFULLY!** This is the **only** opportunity to make minor changes to your article.
- Change only what is incorrect in the article. Limit your changes to **actual, necessary corrections** (not cosmetic, stylistic changes).
- It is the corresponding author's responsibility to ensure that all Disclosure information for each author is accurate and true.
- By returning the corrected page proofs (or approving the article as it now stands), the corresponding author attests to the fact that the final version of the paper has been approved by all authors.
- Substantive changes will require re-review of the article, leading to a delay in publication.
- Requested changes will be made at the discretion of the Editor.

Only one set of corrections will be accepted; please collaborate with your co-authors so that we do not receive conflicting corrections from several authors.

Note that the page proof PDF is a low-resolution file to reduce file size and download times. Figures in your article will appear as high-resolution images in the published versions of your article.

Not for Reprint

Authors: Please review all authors' names, academic degrees, affiliations, and contributions (in the *Disclosure*) for spelling and accuracy.

MS# 13-787, author proof

Not for Reprint

DOI: 10.3171/2014.4.JNS13787
©AANS, 2014

Patients' cosmetic satisfaction, pain, and functional outcomes after supraorbital craniotomy through an eyebrow incision

Clinical article

Robert Reisch, M.D.,[1] Hani J. Marcus, M.R.C.S.,[1,2] Michael Hugelshofer, M.D.,[1] Nicolas Olmo Koechlin, M.D.,[1] Axel Stadie, M.D.,[3] and Ralf A. Kockro, M.D.[1]

[1]Centre for Endoscopic and Minimally Invasive Neurosurgery, Klinik Hirslanden, Zurich, Switzerland; [2]Imperial College Healthcare NHS Trust, London, United Kingdom; and [3]Neurosurgical Department, University Hospital Mainz, Mainz, Germany

Object. The supraorbital approach through an eyebrow incision offers the opportunity to access a wide variety of lesions of the anterior, middle, and even the posterior fossa. The minimally invasive keyhole craniotomy limits brain exploration and retraction and offers the potential for improved surgical outcomes and reduced approach-related complications. Patient satisfaction, however, has not yet been reported in the literature.

Methods. From January 2002 through December 2011, the lead author (R.R.) used a supraorbital approach through an eyebrow incision for 418 patients with cerebral aneurysms, brain tumors or cystic lesions, and other miscellaneous pathological conditions. For 408 of these patients, a detailed retrospective case note review was conducted to extract data on surgical outcomes and complications, and 375 patients completed a follow-up patient satisfaction questionnaire.

Results. During the early perioperative period, 8 patients died (overall mortality rate 2.0%). Among patients surveyed, the overall level of satisfaction was high. Patients rated pain from the scar and headache on a scale from 1 to 5 (1 = no pain, 5 = severe pain) as follows: pain was a score of 1 for 289 patients (77.0%), 2 for 46 (12.3%), 3 for 22 (5.9%), 4 for 12 (3.2%), and 5 for 6 (1.6%). Patients also rated cosmetic outcome on a scale from 1 to 5 (1 = very pleasant, 5 = very unpleasant) as follows: outcome was a score of 1 for 315 patients (84.0%), 2 for 33 (8.8%), 3 for 14 (3.7%), 4 for 10 (2.7%), and 5 for 3 (0.8%). Postoperative chewing difficulty was reported for 8 patients (8 [2.1%] temporary, 0 permanent); palsy of the frontal muscle for 21 patients (5.6%; 13 [3.5%] temporary, 8 [2.1%] permanent); frontal hypesthesia for 31 patients (8.3%; 18 [4.8%] temporary, 13 [3.4%] permanent); and hyposmia for 11 patients (2.9%; 3 [0.8%] temporary, 8 [2.1%] permanent).

Conclusions. The supraorbital approach to the anterior, middle, and posterior fossae through an eyebrow incision offers a favorable rate of approach-associated surgical complications and high patient satisfaction with cosmetic outcome.
(http://thejns.org/doi/abs/10.3171/2014.4.JNS13787)

Key Words • **eyebrow skin incision** • **supraorbital approach** • **minimally invasive neurosurgery** • **patient satisfaction** • **surgical complications** • **surgical outcome** • **surgical technique**

A number of experimental and clinical studies have shown that brain retraction substantially traumatizes brain tissue and can cause permanent neurological deficits.[1–3,12–14,25] In addition, exploration of brain tissue for several hours can lead to injury of the cortical surface through exposure to nonphysiological surroundings. To reduce trauma to the brain, various methods have been proposed, including use of anesthetic techniques to lessen cerebral edema, patient-positioning techniques to encourage brain relaxation, and specially designed brain retractor systems and instruments to decrease the forces exerted on delicate neural tissue. Along with these methods, the use of custom, tailored, minimally invasive keyhole techniques to limit exposure and manipulation of unaffected brain tissue can further reduce approach-associated complications.[10,17,22,23,27] The cosmetic deformities that appear after a frontotemporal pterional craniotomy usually result from a lesion of the frontotemporal branch of the facial nerve or atrophy of the temporal muscle and substantially decrease the patient's quality of life.

Not for Reprint

The supraorbital keyhole approach through an eyebrow incision offers access to a wide range of lesions of the anterior, middle, and even the posterior fossa.[5–7,9,15,18,19,24,26] Although the operative technique, surgical outcomes, and complications of this approach have been described briefly, to our knowledge patient satisfaction has not yet been reported in the literature.

Methods

Surgical Technique

The same surgical technique, reported elsewhere,[20,21] was used for all patients. In brief, the patients were placed supine in a 3-point Mayfield head holder (Codman, Inc.). The skin was incised in the lateral part of the eyebrow. The subcutaneous layer was dissected, and the skin flap was retracted in the frontal direction. Using a monopolar knife, the frontal muscle was divided parallel to the orbital rim; after the temporal line was reached, the monopolar blade was turned 90° and then followed the temporal line in a basal direction to the zygomatic process of the frontal bone. A high-speed drill and punches were used to fashion a single frontobasal bur hole posterior to the temporal line at the level of the frontal cranial base. A high-speed craniotome was used to cut a straight line parallel to the orbital rim in a lateral-to-medial direction, and subsequently, a C-shaped line was cut from the bur hole to the medial border of the previously created frontobasal line. This procedure produces an approximately 20 × 15–mm craniotomy. After the inner edge of the craniotomy above was drilled, the orbital rim was opened in a C-shaped flap and retracted in a basal direction.

After completion of the intracranial procedure, the dura was sutured, the bone flap was replaced with a CranioFix plate (Aesculap AG), and any craniotomy defects were filled with bone cement to create a pleasing cosmetic outcome. The muscles were reapproximated, and the skin was closed with subcutaneous and subcuticular sutures.

Retrospective Evaluation

During the 10-year study period, the supraorbital approach was used for 418 patients. For every patient, the supraorbital approach was performed after careful preoperative study of diagnostic images to determine the least traumatic route to the lesion, taking into consideration each patient's particular pathoanatomical factors.

Case notes and images were available for 408 patients with varying pathological conditions (Table 1). In addition, 375 available patients were contacted and completed a follow-up patient satisfaction questionnaire. Patients were asked to rate postoperative scar pain and headache on a scale from 1 to 5 (1 = no pain, 5 = severe pain), postoperative cosmesis on a scale from 1 to 5 (1 = very pleasant, 5 = very unpleasant), difficulty chewing, frontal weakness, frontal hypesthesia, and hyposmia.

To evaluate the surgical learning curve involved in performing supraorbital craniotomy, we evaluated satisfaction of the first 50 and last 50 patients who underwent the procedure. We compared responses by using the Fisher exact or chi-square test.

TABLE 1: Pathological conditions treated by supraorbital craniotomy, January 2002 through December 2011

Condition	No. of Patients
aneurysm	240
meningioma	96
pituitary adenoma	10
craniopharyngioma	22
astrocytoma	7
epidermoid cyst	12
metastases	6
arachnoid cyst	2
arteriovenous malformation	2
cavernoma	8
germinoma	3
total	408

Results

Deaths

During the 30-day perioperative period, 8 patients died. Causes of death were hemorrhage (n = 1), pulmonary embolism (n = 1), and severe vasospasms after aneurysmal subarachnoid hemorrhage (n = 6); the overall mortality rate was 2.0%.

Approach-Associated Complications

Postoperative hemorrhage occurred in 7 patients (1.7%); among these, urgent surgery was needed for 2 (0.5%). Postoperative CT images demonstrated subdural hygromas in 6 patients (1.5%), among whom surgery was needed in 2 (0.5%). Wound-healing disturbances occurred in 5 patients (1.2%), among whom removal of the bone flap was needed in 1 (0.2%) because of wound suppuration. For 18 (4.4%) patients, a subcutaneous CSF pouch was observed and successfully managed conservatively for all. A total of 5 patients (1.2%) experienced a postoperative CSF leak, 3 through the frontal sinus and 2 through the deep paranasal sinuses after removal of the anterior clinoid process. Transient palsy of the frontal muscle was reported for 13 (3.5%) patients and permanent palsy for 8 (2.1%). Problems with closure of the eyelid were not reported for any patient. Transient frontal hypesthesia was reported for 18 patients (4.8%) and permanent deficit for 13 (3.4%). Postoperative epileptic seizures occurred in 1 patient (0.2%). Transient hyposmia was reported for 3 patients (0.8%) and permanent hyposmia for 8 (2.1%); all of these patients harbored meningioma in or near the olfactory groove. Postoperative approach-associated complications of the eyebrow incision and supraorbital craniotomy are summarized in Table 2.

Patient Satisfaction

Postoperative scar pain and headache were reported as "none" or "minimal" (score of 1 or 2) by 335 patients (89.3%) (Table 3). The cosmetic outcome was reported as "very pleasant" or "quite pleasant" by 348 patients

Not for Reprint

TABLE 2: Postoperative approach-associated complications after supraorbital craniotomy through an eyebrow incision

Complication Type	No. of Complications (%)		
	Temporary	Permanent	Total
difficulty chewing	8 (2.1)	0 (0)	8 (2.1)
palsy of frontalis muscle	13 (3.5)	8 (2.1)	21 (5.6)
frontal hypesthesia	18 (4.8)	13 (3.4)	31 (8.3)
hyposmia	3 (0.8)	8 (2.1)	11 (2.9)

(92.8%) (Table 4). Among patients who were not entirely satisfied, most described a small indentation behind the temporal line, where the bur hole trephination had been performed. Postoperative problems with chewing were described by 8 patients (2.1%).

Surgical Learning Curve

In a comparison between the first 50 and last 50 cases performed, statistically significant reductions in postoperative facial palsy, hyposmia, and improvement in patient satisfaction with cosmetic outcome were noted ($p < 0.05$). In the same comparison, no significant differences in postoperative scar pain and headache, frontal numbness, or problems with chewing were noted.

Discussion

The extent of acceptance and adoption of the supraorbital approach will depend on the satisfaction of neurosurgeons and their patients. Surgeons will be satisfied if the approach offers reduced intraoperative traumatization, shorter operating times, and shorter hospitalization times while equaling or exceeding the safety and efficacy profile of conventional approaches. Patients will be satisfied if, in addition to the aforementioned factors, the approach is associated with less pain, improved cosmesis, and fewer postoperative complaints.

Our case series has demonstrated that the keyhole supraorbital approach can be performed with excellent surgical outcomes and very few associated complications. The neurosurgical advantages of limited approaches are well known.[4,8,9,11,14,17] A supraorbital craniotomy through an eyebrow incision can provide a more direct approach to pathological conditions and can reduce the time from skin incision to durotomy to approximately 15 minutes, providing the potential for shorter operating times.[26] Moreover, the smaller skin incision, limited soft-tissue dissection, and minimal brain exposure and retraction can reduce associated postoperative complications. However, keyhole approaches also have shortcomings, especially with regard to surgical safety.[17] Because microsurgical dissection through a keyhole approach substantially limits the surgeon's working space, gaining experience with this procedure is associated with a steep learning curve, which may expose patients to higher intraoperative risk.

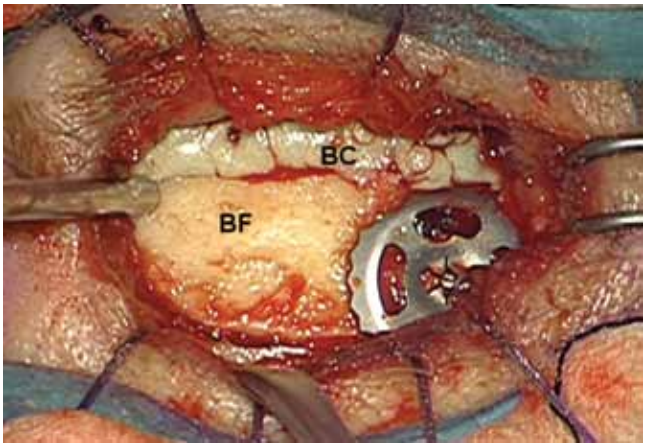

Fig. 1. Fixation of the bone flap (BF). Remaining defects are filled with bone cement (BC) to prevent indentation of the overlying skin.

Patient satisfaction with the approach was good. Patients reported that the short skin incision within the eyebrow and the single bur hole trephination behind the temporal line offered pleasing cosmetic results. Patients also reported acceptable severity of postoperative complaints, the most common being frontal hypesthesia and paresis, which persisted for 3.4% and 2.1% patients, respectively. Throughout the case series, a learning curve was demonstrated by improved cosmesis and less occurrence of frontal muscle paresis over time. Because patients who were not entirely satisfied often described a small indentation behind the temporal line, where bur hole trephination was performed, we speculate that improvements might result in part from more careful placement and fixation of the bone flap. During the study period, we modified the closure technique to cover the bur hole with a Craniofix plate and bone cement (Fig. 1).

We also assessed complications and death associated with the supraorbital approach. However, because the patient population in this single-surgeon series is very heterogeneous in terms of the pathological conditions treated, we refrained from comparing outcome end points, such as complications and death, between our study and others.

For all patients in our study, self-absorbable cuticular sutures were used. It is a matter of debate whether the breakdown of absorbable suture materials causes an inflammatory reaction, which might lead to more pronounced scarring. However, Parell and Becker, in a prospective study of 41 patients who underwent excision of

TABLE 3: Postoperative discomfort after supraorbital craniotomy through an eyebrow incision in 375 patients*

Factor	Scale Score (%)				
	1	2	3	4	5
no. of cases	289 (77.0)	46 (12.3)	22 (5.9)	12 (3.2)	6 (1.6)

* Score scale: 1 = no pain; 5 = severe pain.

Not for Reprint

TABLE 4: Satisfaction with the postoperative cosmetic outcome after supraorbital craniotomy through an eyebrow incision in 375 patients*

Factor	Scale Score (%)				
	1	2	3	4	5
no. of cases	315 (84.0)	33 (8.8)	14 (3.7)	10 (2.7)	3 (0.8)

* Score scale: 1 = very satisfied; 5 = very unsatisfied.

facial skin cancer, found no significant difference in aesthetic outcome between patients in whom absorbable or nonabsorbable intracutaneous sutures were used to close facial skin wounds.[16]

The supraorbital approach requires very careful case selection, detailed preoperative planning, and meticulous execution of the surgical procedure along with use of modern imaging guidance and specific microinstruments to ensure safety and effectiveness.[17,22] Because the outcomes improved with surgical experience, colleagues who are new to this technique should be closely guided through all stages of the operation. In addition, the beginning and closure of the operation should not be left to residents who have not been properly trained with this technique.

Essential limitations of our study arise from the retrospective nature of the case series, possible case-selection and self-reporting bias, and incomplete follow-up for the entire cohort. Additionally, to our knowledge, this is the first study with regard to patient satisfaction of the supraorbital approach; as a result, a comparison with previous data is not possible.

Conclusions

We have presented a series of cases for which the lead author (R.R.) performed supraorbital craniotomy through an eyebrow incision; we evaluated surgical efficacy and safety as well as patient satisfaction. For the 418 patients who underwent surgery through the supraorbital approach during the 10-year study period, the rate of approach-associated complications was favorable and the cosmetic satisfaction of surveyed patients was high.

Acknowledgments

Operations were performed at the Neurosurgical Department of the University Hospital Mainz, Germany; at the University Hospital Zurich, Switzerland; and at the Klinik Hirslanden Zurich, Switzerland. Special thanks are given to colleagues who supported the teamwork of endoscope-assisted neurosurgery. This paper is dedicated to the memory of Prof. Axel Perneczky, our teacher of minimally invasive techniques and a pioneer of the supraorbital keyhole approach.

Disclosure

Twice a year Dr. Stadie works as a tutor for courses on minimally invasive/endoscopic technique held by Aesculap Akademie, which provides an allowance for this work.

Author contributions to the study and manuscript preparation include the following. Conception and design: Reisch, Marcus. Acquisition of data: Reisch, Marcus. Analysis and interpretation of data: Reisch, Marcus, Kockro. Drafting the article: Reisch, Marcus, Hugelshofer, Koechlin, Stadie. Critically revising the article: all authors. Reviewed submitted version of manuscript: all authors. Approved the final version of the manuscript on behalf of all authors: Reisch. Study supervision: Kockro.

References

1. Albin MS, Bunegin L, Bennett MH, Dujovny M, Jannetta PJ: Clinical and experimental brain retraction pressure monitoring. **Acta Neurol Scand Suppl 64:**522–523, 1977
2. Albin MS, Bunegin L, Dujovny M, Bennett MH, Jannetta PJ, Wisotzkey HM: Brain retraction pressure during intracranial procedures. **Surg Forum 26:**499–500, 1975
3. Andrews RJ, Bringas JR: A review of brain retraction and recommendations for minimizing intraoperative brain injury. **Neurosurgery 33:**1052–1064, 1993
4. Beretta F, Andaluz N, Chalaala C, Bernucci C, Salud L, Zuccarello M: Image-guided anatomical and morphometric study of supraorbital and transorbital minicraniotomies to the sellar and perisellar regions: comparison with standard techniques. Laboratory investigation. **J Neurosurg 113:**975–981, 2010
5. Cohen AR, Perneczky A, Rodziewicz GS, Gingold SI: Endoscope-assisted craniotomy: approach to the rostral brain stem. **Neurosurgery 36:**1128–1130, 1995
6. Czirják S, Nyáry I, Futó J, Szeifert GT: Bilateral supraorbital keyhole approach for multiple aneurysms via superciliary skin incisions. **Surg Neurol 57:**314–324, 2002
7. Czirják S, Szeifert GT: Surgical experience with frontolateral keyhole craniotomy through a superciliary skin incision. **Neurosurgery 48:**145–150, 2001
8. Figueiredo EG, Deshmukh V, Nakaji P, Deshmukh P, Crusius MU, Crawford N, et al: An anatomical evaluation of the mini-supraorbital approach and comparison with standard craniotomies. **Neurosurgery 59:**ONS212–ONS220, 2006
9. Fries G, Perneczky A: Endoscope-assisted brain surgery: part 2—analysis of 380 procedures. **Neurosurgery 42:**226–232, 1998
10. Fries G, Reisch R: Biportal neuroendoscopic microsurgical approaches to the subarachnoid cisterns. A cadaver study. **Minim Invasive Neurosurg 39:**99–104, 1996
11. Hernesniemi J, Ishii K, Niemelä M, Smrcka M, Kivipelto L, Fujiki M, et al: Lateral supraorbital approach as an alternative to the classical pterional approach. **Acta Neurochir Suppl 94:**17–21, 2005
12. Hongo K, Kobayashi S, Yokoh A, Sugita K: Monitoring retraction pressure on the brain. An experimental and clinical study. **J Neurosurg 66:**270–275, 1987
13. Jadhav V, Zhang JH: Surgical brain injury: prevention is better than cure. **Front Biosci 13:**3793–3797, 2008
14. Krayenbühl N, Oinas M, Erdem E, Krisht AF: The impact of minimizing brain retraction in aneurysm surgery: evaluation using magnetic resonance imaging. **Neurosurgery 69:**344–348, 2011
15. Menovsky T, Grotenhuis JA, de Vries J, Bartels RH: Endoscope-assisted supraorbital craniotomy for lesions of the interpeduncular fossa. **Neurosurgery 44:**106–112, 1999
16. Parell GJ, Becker GD: Comparison of absorbable with nonabsorbable sutures in closure of facial skin wounds. **Arch Facial Plast Surg 5:**488–490, 2003

Not for Reprint

17. Perneczky A, Fries G: Endoscope-assisted brain surgery: part 1—evolution, basic concept, and current technique. **Neurosurgery 42:**219–225, 1998
18. Ramos-Zúñiga R, Velázquez H, Barajas MA, López R, Sánchez E, Trejo S: Trans-supraorbital approach to supratentorial aneurysms. **Neurosurgery 51:**125–131, 2002
19. Reisch R, Perneczky A: Ten-year experience with the supraorbital subfrontal approach through an eyebrow skin incision. **Neurosurgery 57 (4 Suppl):**242–255, 2005
20. Reisch R, Perneczky A, Filippi R: Surgical technique of the supraorbital key-hole craniotomy. **Surg Neurol 59:**223–227, 2003
21. Reisch R, Stadie A, Kockro R, Gawish I, Schwandt E, Hopf N: The minimally invasive supraorbital subfrontal key-hole approach for surgical treatment of temporomesial lesions of the dominant hemisphere. **Minim Invasive Neurosurg 52:**163–169, 2009
22. Reisch R, Stadie A, Kockro RA, Hopf N: The keyhole concept in neurosurgery. **World Neurosurg 79 (2 Suppl):**S17.e9– S17.e13, 2013
23. Romani R, Silvasti-Lundell M, Laakso A, Tuominen H, Hernesniemi J, Niemi T: Slack brain in meningioma surgery through lateral supraorbital approach. **Surg Neurol Int 2:**167, 2011
24. Steiger HJ, Schmid-Elsaesser R, Stummer W, Uhl E: Transorbital keyhole approach to anterior communicating artery aneurysms. **Neurosurgery 48:**347–352, 2001
25. Thiex R, Hans FJ, Krings T, Sellhaus B, Gilsbach JM: Technical pitfalls in a porcine brain retraction model. The impact of brain spatula on the retracted brain tissue in a porcine model: a feasibility study and its technical pitfalls. **Neuroradiology 47:**765–773, 2005
26. van Lindert E, Perneczky A, Fries G, Pierangeli E: The supraorbital keyhole approach to supratentorial aneurysms: concept and technique. **Surg Neurol 49:**481–490, 1998
27. Wilson DH: Limited exposure in cerebral surgery. Technical note. **J Neurosurg 34:**102–106, 1971

Manuscript submitted April 18, 2013.
Accepted April 3, 2014.
Please include this information when citing this paper: published online Month Day, Year; DOI: 10.3171/2014.4.JNS13787.
Address correspondence to: Robert Reisch, M.D., Centre for Endoscopic and Minimally Invasive Neurosurgery, Klinik Hirslanden, Witellikerstr. 40, Zurich 8032, Switzerland. email: robert.reisch@hirslanden.ch.

Not for Reprint